

## EASL Clinical Practice Guidelines: Management of cholestatic liver diseases

European Association for the Study of the Liver\*

**Keywords:** Primary biliary cirrhosis; Primary sclerosing cholangitis; Overlap syndrome; Immunoglobulin G4-associated cholangitis; Drug-induced cholestatic liver disease; Genetic cholestatic liver disease; Cholestatic liver diseases in pregnancy; Intrahepatic cholestasis of pregnancy; Fatigue; Pruritus

### 1. Introduction

EASL Clinical Practice Guidelines (CPG) on the management of cholestatic liver diseases define the use of diagnostic, therapeutic and preventive modalities, including non-invasive and invasive procedures, in the management of patients with cholestatic liver diseases. They are intended to assist physicians and other health-care providers as well as patients and interested individuals in the clinical decision-making process by describing a range of generally accepted approaches for the diagnosis, treatment and prevention of specific

cholestatic liver diseases. The clinical care for patients with cholestatic liver diseases has advanced considerably during recent decades thanks to growing insight into pathophysiological mechanisms and remarkable methodological and technical developments in diagnostic procedures as well as therapeutic and preventive approaches. Still, various aspects in the care of patients with cholestatic disorders remain incompletely resolved. The EASL CPG on the management of cholestatic liver diseases aim to provide current recommendations on the following issues:

- Diagnostic approach to the cholestatic patient.
- Diagnosis and treatment of primary biliary cirrhosis (PBC).
- Diagnosis and treatment of PBC–autoimmune hepatitis (AIH) overlap syndrome.
- Diagnosis and treatment of primary sclerosing cholangitis (PSC).
- Diagnosis and treatment of PSC–AIH overlap syndrome.
- Diagnosis and treatment of immunoglobulin G4-associated cholangitis (IAC).

\* EASL Office, 7 rue des Batoirs, 1205 Geneva, Switzerland. Tel.: +41 22 8070360; fax: +41 22 3280724.

E-mail address: easloffice@easloffice.eu

**Abbreviations:** AIH, autoimmune hepatitis; AIP, autoimmune pancreatitis; AMA, antimitochondrial antibodies; AP, alkaline phosphatase in serum; ASMA, anti-smooth muscle antibodies; BRIC, benign recurrent intrahepatic cholestasis; CCA, cholangiocarcinoma; CF, cystic fibrosis; CFALD, cystic fibrosis-associated liver disease; CPG, Clinical Practice Guidelines; CT, computed tomography; DILI, drug-induced liver injury; EASL, European Association for the Study of the Liver; ERCP, endoscopic retrograde cholangiopancreatography; EUS, endoscopic ultrasound; FDG-PET, (<sup>18</sup>F)-fluoro-deoxy-D-glucose positron emission tomography; FXR, farnesoid X receptor;  $\gamma$ GT,  $\gamma$ -glutamyltranspeptidase in serum; HCC, hepatocellular carcinoma; IAC, immunoglobulin G4-associated cholangitis; IAIHG, International Autoimmune Hepatitis Group; IBD, inflammatory bowel disease; IgG, immunoglobulin G in serum; IgG4, immunoglobulin G4 in serum; MRCP, magnetic resonance cholangiopancreatography; NASH, non-alcoholic steatohepatitis; PBC, primary biliary cirrhosis; PDC-E2, E2 subunit of the pyruvate dehydrogenase complex; PSC, primary sclerosing cholangitis; PIINP, procollagen-3-aminoterminal propeptide; UC, ulcerative colitis; ULN, upper limit of normal; US, ultrasound.

**Contributors:** Clinical Practice Guidelines Panel: Ulrich Beuers, Kirsten M. Boberg, Roger W. Chapman, Olivier Chazouillères, Pietro Invernizzi, David E.J. Jones, Frank Lammert, Albert Parès, Michael Trauner; **Reviewers:** Antonio Benedetti, Peter L.M. Jansen, Hanns-Ulrich Marschall, James Neuberger, Gustav Paumgartner, Raoul Poupon, Jesús Prieto.

- Diagnosis and treatment of drug-induced cholestatic liver diseases.
- Diagnosis and treatment of genetic cholestatic liver diseases.
- Diagnosis and treatment of cholestatic liver diseases in pregnancy.
- Treatment of extrahepatic manifestations of cholestatic liver diseases.

**Table 1a**  
Categories of evidence.

Grade	Evidence
I	Randomized controlled trials
II-1	Controlled trials without randomization
II-2	Cohort or case-control analytic studies
II-3	Multiple time series, dramatic uncontrolled experiments
III	Opinions of respected authorities, descriptive epidemiology

A panel of experts selected by the EASL Governing Board in May 2008 wrote and discussed these guidelines between June and November 2008. These guidelines have been produced using evidence from PubMed and Cochrane database searches before 1 October, 2008. Where possible, the level of evidence and recommendation are cited (Tables 1a, 1b). The evidence and recommendations in these guidelines have been graded according to the Grading of Recommendations Assessment Development and Evaluation (GRADE system) [1]. The strength of recommendations thus reflects the quality of underlying evidence which has been classified in one of three levels: high [A], moderate [B] or low-quality evidence [C]. The GRADE system offers two grades of recommendation: strong [1] or weak [2] (Table 1b). The CPG thus consider the quality of evidence: the higher, the more likely a strong recommendation is warranted; the greater the variability in values and preferences, or the greater the uncertainty, the more likely a weaker recommendation is warranted.

**Table 1b**  
Evidence grading (adapted from the GRADE system [1]).

Evidence	Notes	
High quality	Further research is very unlikely to change our confidence in the estimate of effect	A
Moderate quality	Further research is likely to have an important impact on our confidence in the estimate of effect and may change the estimate	B
Low quality	Further research is very likely to have an important impact on our confidence in the estimate of effect and is likely to change the estimate. Any change of estimate is uncertain	C
<b>Recommendation</b>		
Strong	Factors influencing the strength of the recommendation included the quality of the evidence, presumed patient-important outcomes, and cost	1
Weak	Variability in preferences and values, or more uncertainty. Recommendation is made with less certainty, higher cost or resource consumption	2

Where no clear evidence exists, guidance is based on the consensus advice of expert opinion in the literature and the writing committee.

## 2. Diagnostic approach to cholestasis

Cholestasis is an impairment of bile formation and/or bile flow which may clinically present with fatigue, pruritus and, in its most overt form, jaundice. Early biochemical markers in often asymptomatic patients include increases in serum alkaline phosphatase (AP) and  $\gamma$ -glutamyltranspeptidase ( $\gamma$ GT) followed by conjugated hyperbilirubinemia at more advanced stages. Cholestasis may be classified as intrahepatic or extrahepatic. Intrahepatic cholestasis may result from hepatocellular functional defects or from obstructive lesions of the intrahepatic biliary tract distal from bile canaliculi. Cholestasis may also be related to mixed mechanisms in diseases such as lymphoma [2]. By convention, cholestasis is considered chronic if it lasts >6 months. Most chronic cholestatic diseases are purely intrahepatic, whereas sclerosing cholangitis may affect small and large intrahepatic and/or extrahepatic bile ducts. Asymptomatic patients are generally identified when routine laboratory tests are being performed or during work-up for another disease when an increase is noted in the serum level of AP and/or  $\gamma$ GT. Isolated serum  $\gamma$ GT elevation has little specificity for cholestasis, and may also result from enzyme induction in response to alcohol or drug intake. Isolated serum AP elevation is seen in cholestatic liver diseases including certain rare disorders (e.g., progressive familial intrahepatic cholestasis (PFIC) 1 & 2, bile acid synthesis defects), but may also result from rapid bone growth (e.g., in children), bone disease (e.g., Paget's disease), or pregnancy. The cut-off levels of serum AP and  $\gamma$ GT requiring diagnostic work-up are debated: AP levels higher than 1.5 times the upper limit of normal (ULN) and  $\gamma$ GT levels >3 $\times$  ULN have been proposed. The differential diagnosis of cholestatic disorder

ders can be wide (Table 2). Nevertheless, the first critical step is to differentiate intra- and extrahepatic cholestasis.

Careful patient history and physical examination are essential in the diagnostic process and may provide valuable information so that an experienced clinician can predict the nature of cholestasis in many cases [3]. Presence of extrahepatic diseases has to be recorded. A thorough occupational and drug history is imperative and any medications taken within 6 weeks of presentation may be incriminated (and discontinued); this includes herbal medicines, vitamins and other substances. A history of fever, especially when accompanied by rigors or right upper quadrant abdominal pain is suggestive of cholangitis due to obstructive diseases (particularly choledocholithiasis), but may be seen in alcoholic disease and rarely, viral hepatitis. A history of prior biliary surgery also increases the likelihood that biliary obstruction is present. Finally, a family history of cholestatic liver disease suggests a possibility of a hereditary disorder. Some cholestatic disorders are observed only under certain circumstances (e.g., pregnancy, childhood, liver transplantation, HIV-infection), and may require specific investigations that are not relevant in other populations.

Abdominal ultrasonography is usually the first step to exclude dilated intra- and extrahepatic ducts and

mass lesions because it is rather sensitive and specific, non-invasive, portable and relatively inexpensive. Its disadvantages are that its findings are operator-dependent and abnormalities of bile ducts such as those observed in sclerosing cholangitis may be missed. Furthermore, the lower common bile duct and pancreas are usually not well depicted. Computed tomography of the abdomen is less interpreter-dependent, but is associated with radiation exposure and may be not as good as ultrasound at delineating the biliary tree.

If bile duct abnormalities are present, further work-up depends on the presumed cause. From a purely diagnostic perspective, magnetic resonance cholangiopancreatography (MRCP) is a safe option to explore the biliary tree. Its accuracy for detecting biliary tract obstruction approaches that of endoscopic retrograde cholangiopancreatography (ERCP) when performed in experienced centres with state-of-the-art technology. Endoscopic ultrasound (EUS) is equivalent to MRCP in the detection of bile duct stones and lesions causing extrahepatic obstruction and may be preferred to MRCP in endoscopic units.

Extrahepatic biliary obstruction may be caused by stones, tumours, cysts, or strictures. The gold standard for visualizing the biliary tract and treating extrahepatic biliary obstruction is endoscopic retrograde cholangiopancreatography (ERCP), but even in experienced hands it carries a significant complication rate (pancreatitis in 3–5% of cases; when combined with sphincterotomy, bleeding 2%, cholangitis 1%, procedure-related mortality 0.4% [4]). Thus, when extrahepatic obstruction is considered and the need for endoscopic intervention is unclear, MRCP or EUS should be performed in order to avoid ERCP if it is not needed [3].

If imaging studies do not demonstrate mechanical obstruction, a diagnosis of intrahepatic cholestasis can be reasonably made. However, in an individual whose history suggests an extrahepatic cause (like early pancreatic or ampullary carcinoma), clinical judgment should

**Table 2a**

**Causes of intrahepatic cholestasis in adulthood.**

**Hepatocellular cholestasis**

Sepsis-, endotoxemia-induced cholestasis  
 Cholestatic variety of viral hepatitis  
 Alcoholic or non-alcoholic steatohepatitis  
 Drug- or parenteral nutrition-induced cholestasis  
 Genetic disorders: e.g., BRIC, PFIC, ABCB4 deficiency, intrahepatic cholestasis of pregnancy (ICP), erythropoietic protoporphyria  
 Malignant infiltrating disorders: e.g., hematologic diseases, metastatic cancer  
 Benign infiltrating disorders: e.g., amyloidosis, sarcoidosis hepatitis and other granulomatoses, storage diseases  
 Paraneoplastic syndromes: e.g., Hodgkin disease, renal carcinoma  
 Ductal plate malformations: e.g., congenital hepatic fibrosis  
 Nodular regenerative hyperplasia  
 Vascular disorders: e.g., Budd–Chiari syndrome, veno-occlusive disease, congestive hepatopathy  
 Cirrhosis (any cause)

**Cholangiocellular cholestasis**

Primary biliary cirrhosis (AMA+/AMA–)  
 Primary sclerosing cholangitis  
 Overlap syndromes of PBC and PSC with AIH  
 IgG4-associated cholangitis  
 Idiopathic adulthood ductopenia  
 Ductal plate malformations: biliary hamartoma, Caroli syndrome  
 Cystic fibrosis  
 Drug-induced cholangiopathy  
 Graft vs. host disease  
 Secondary sclerosing cholangitis: e.g., due to various forms of cholangiolithiasis, ischemic cholangiopathies (hereditary hemorrhagic telangiectasia, polyarteritis nodosa and other forms of vasculitis), infectious cholangitis related to AIDS and other forms of immunodepression, etc.

**Table 2b**

**Causes of intrahepatic cholestasis in infancy and childhood [2].**

Metabolic disease  
 – with biliary tract involvement:  $\alpha$ 1-antitrypsin storage disease, cystic fibrosis  
 – without biliary tract involvement: galactosemia, tyrosinemia, fatty acid oxidation defects, lipid and glycogen storage disorders, peroxisomal disorders  
 – specific defects in biliary function:  
 disorders of bile acid biosynthesis and conjugation  
 disorders of canalicular secretion (PFIC)  
 Paucity of bile ducts  
 – syndromic: Alagille syndrome (Jagged 1 defect)  
 – non-syndromic  
 Ductal plate malformations  
 Infections: bacterial, viral  
 Toxic: parenteral nutrition, drugs  
 Idiopathic neonatal hepatitis  
 Cirrhosis (any cause)

be pursued and repeat ultrasound or another imaging procedure should be performed [3].

When extrahepatic obstruction has been reasonably excluded, further work-up of intrahepatic cholestasis (Table 2) depends on the clinical setting.

In adult patients with chronic intrahepatic cholestasis, the next step is testing for serum antimitochondrial antibodies (AMA) since the diagnosis of PBC, which is the major cause of small-duct biliary diseases [5], can be made with confidence in a patient with high-titer AMA ( $\geq 1/40$ ) and a cholestatic serum enzyme profile in the absence of an alternative explanation [6]. A liver biopsy may still be appropriate in selected patients. If AMA and PBC-specific antinuclear antibodies (ANA) are negative, MRCP (in a specialized centre) may be the next diagnostic step for most patients with chronic intrahepatic cholestasis of unknown cause.

Subsequently, a liver biopsy should be performed when the diagnosis is still unclear. Particular attention to the condition of bile ducts is critical in the histologic evaluation and a biopsy of adequate quality should contain  $\geq 10$  portal fields because of the high degree of sampling variability in patients with small bile duct disease. Biopsy findings should be classified under (i) disorders involving bile ducts (for typical biliary lesions, see Table 3) the main causes being AMA-negative PBC, isolated small duct PSC, ABCB4 deficiency, sarcoidosis, idiopathic ductopenia or prolonged drug-induced cholestasis; (ii) disorders not involving bile ducts, the main causes being a variety of storage or infiltrative liver diseases, hepatic granulomas (without cholangitis), nodular regenerative hyperplasia, peliosis, sinusoidal dilatation and cirrhosis; and (iii) hepatocellular cholestasis with only minimal histologic abnormalities as observed in benign recurrent intrahepatic cholestasis (BRIC), estrogen or anabolic steroid therapy, sepsis, total parenteral nutrition or as a paraneoplastic phenomenon.

A general algorithm for evaluating the adult patient with cholestasis is presented in Fig. 1.

### Recommendations

1. A detailed history and physical examination are essential (III/C1).
2. Ultrasound is the first-line non-invasive imaging procedure in order to differentiate intra- from extrahepatic cholestasis (III/C1).
3. Testing for serum antimitochondrial antibodies (AMA) is mandatory in adults with chronic intrahepatic cholestasis (III/C1).
4. Magnetic resonance cholangiopancreatography (MRCP) is the next step to be considered in patients with unexplained cholestasis (III/C1).
5. Endoscopic ultrasound (EUS) is an alternative to MRCP for evaluation of distal biliary tract obstruction (II-2/B1).

**Table 3**

**Typical biliary lesions and their main causes (liver transplant setting excluded) [2].**

- 
- |  |  |
|--|--|
| <ol style="list-style-type: none"> <li>1. Nonsuppurative destructive cholangitis           <ul style="list-style-type: none"> <li>Primary biliary cirrhosis</li> <li>Primary sclerosing cholangitis</li> <li>Autoimmune hepatitis</li> <li>Drug-induced cholangitis</li> <li>Sarcoidosis</li> <li>ABCB4 deficiency (Hepatitis C, B, E)</li> </ul> </li> <li>2. Fibrous obliterative cholangitis           <ul style="list-style-type: none"> <li>Primary sclerosing cholangitis</li> <li>Secondary sclerosing cholangitis</li> <li>IgG4-associated cholangitis</li> <li>Sarcoidosis</li> </ul> </li> <li>3. Other cholangitis (unusual)           <ul style="list-style-type: none"> <li>Malignant cholangitis</li> <li>Lymphoma (Hodgkin or non-Hodgkin)</li> <li>Systemic mastocytosis</li> <li>Langerhans cell histiocytosis</li> <li>Neutrophilic cholangitis: neutrophilic dermatosis</li> </ul> </li> <li>4. Ductal plate malformations           <ul style="list-style-type: none"> <li>Biliary hamartomas (von Meyenburg complexes)</li> <li>Caroli syndrome</li> <li>Congenital hepatic fibrosis</li> </ul> </li> </ol> | <ol style="list-style-type: none"> <li>6. Diagnostic endoscopic retrograde cholangiopancreatography (ERCP) should be reserved for highly selected cases (II-2/A1). If the need for a therapeutic maneuver is not anticipated, MRCP or EUS should be preferred to ERCP because of the morbidity and mortality related to ERCP (II-2/A1).</li> <li>7. A liver biopsy should be considered in patients with otherwise unexplained intrahepatic cholestasis and a negative AMA test (III/C1).</li> <li>8. Genetic testing for <i>ABCB4</i> (encoding the canalicular phospholipid export pump), when available, should be considered in patients with a negative AMA test and biopsy findings that might be compatible with PBC or PSC.</li> </ol> |
|--|--|
- 

### 3. Primary biliary cirrhosis (PBC)

#### 3.1. Diagnosis of PBC

Patients with PBC may present with symptoms as fatigue, pruritus and/or jaundice, but the majority of them are asymptomatic at diagnosis. At first presentation, very few patients present in advanced stage of disease and with complications of portal hypertension (ascites, hepatic encephalopathy or esophageal variceal bleeding). Currently, a diagnosis of PBC is made with confidence on a combination of abnormal serum liver tests (elevation of AP of liver origin for at least 6 months) and presence of AMA ( $\geq 1:40$ ) in serum [6]. The diagnosis is confirmed by disclosing characteristic histological features of florid bile duct lesions.

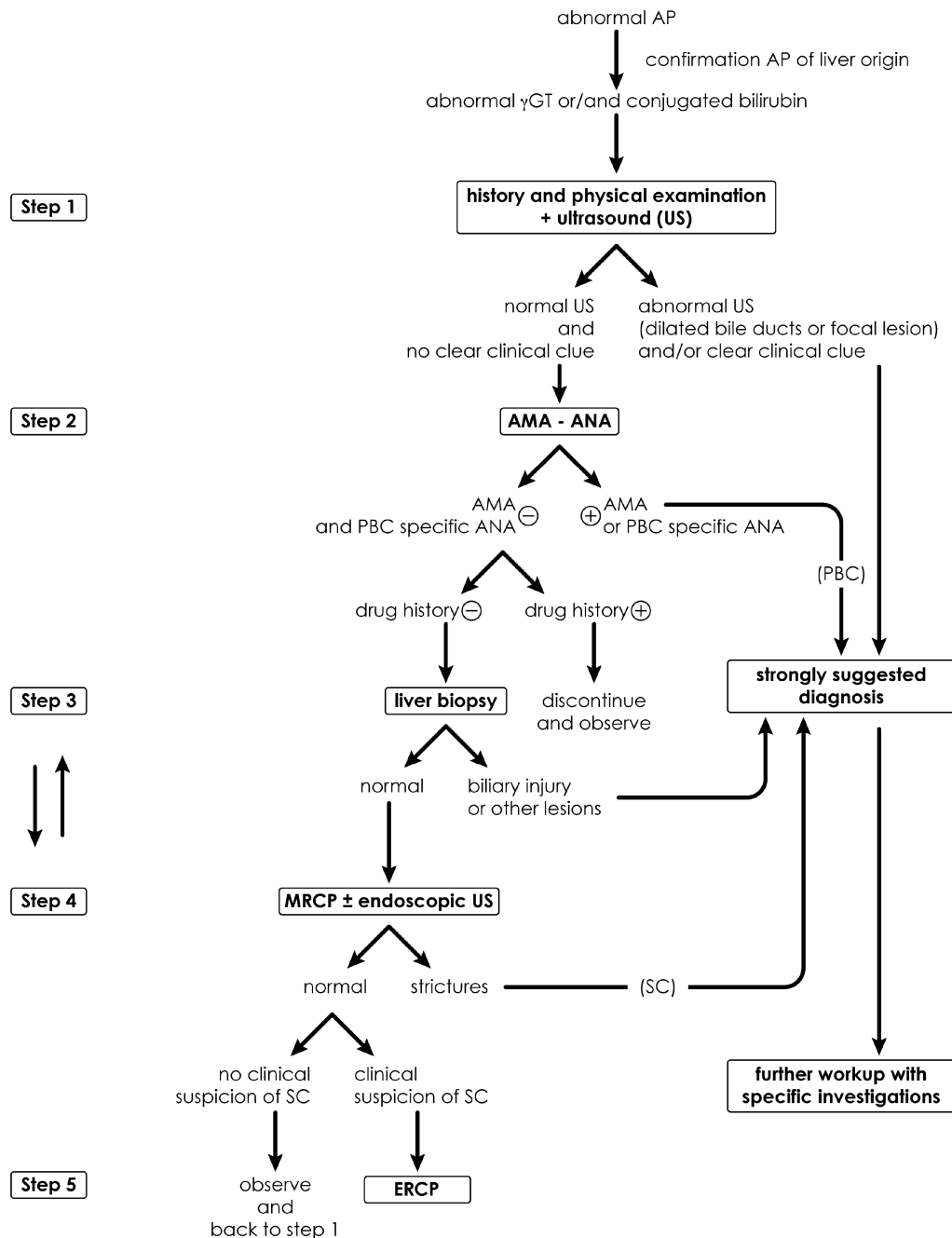


Fig. 1. Diagnostic approach to cholestasis in adult patients. *Abbreviations:* US, ultrasound; CT, computed tomography; AMA, antimitochondrial antibodies; ANA, antinuclear antibodies; MRCP, magnetic resonance cholangiopancreatography; ERCP, endoscopic retrograde cholangiopancreatography; PBC, primary biliary cirrhosis; SC, sclerosing cholangitis.

AMA-positive individuals with normal AP carry a high risk to develop PBC during follow-up [7].

### 3.1.1. Laboratory tests

**Biochemical markers:** Serum AP and  $\gamma$ GT are raised in PBC; serum aminotransferases (ALT, AST) and conjugated bilirubin can also be elevated, but are not diagnostic. Patients with normal AP and  $\gamma$ GT, but with serological stigmata of PBC, should be reassessed clinically and biochemically at annual intervals. Patients

with PBC typically present elevated levels of immunoglobulin M. Serum cholesterol is commonly elevated like in other cholestatic conditions. Alterations in prothrombin time, serum albumin and conjugated bilirubin are observed only in advanced disease.

**Immunological markers:** The diagnostic hallmark of PBC is the presence of AMA, which are detected in serum of more than 90% of affected individuals; the specificity of AMA in PBC is greater than 95% [8]. AMA reactivity is classically studied by immunofluorescence

and considered positive at a titre  $\geq 1/40$  [9]. The identification of the molecular mitochondrial target antigens has allowed the setting up of immunoenzymatic assays with recombinant proteins that raise the sensitivity and specificity of the test. If available, anti-AMA-M2 (anti-PDC-E2) may be a useful alternative. Non-specific anti-nuclear antibodies (ANA) are found in at least 30% of PBC sera. However, ANA directed against nuclear body or envelope proteins such as anti-Sp100 and anti-gp210 which present as multiple [6–12] nuclear dots and perinuclear rims, respectively, at indirect immunofluorescence staining show a high specificity for PBC ( $>95\%$ ) and can be used as markers of PBC when AMA are absent. Their sensitivity, however, is low.

### 3.1.2. Histology

A liver biopsy is no longer regarded as mandatory to make a diagnosis of PBC in patients with a cholestatic serum enzyme pattern and serum AMA. It may, however, be useful for assessment of the activity and staging of the disease. Histological staging of PBC (stages 1–4) has been proposed by Ludwig et al. [10] and Scheuer [11] according to the degree of bile duct damage, inflammation and fibrosis. Focal duct obliteration with granuloma formation has been termed the florid duct lesion, and is judged almost pathognomonic for PBC when present. The liver is not uniformly involved, and features of all four stages of PBC can co-exist simultaneously in a single biopsy. The most advanced histological features should be used for histological staging.

### 3.1.3. Imaging

Abdominal ultrasound examination is indicated in all patients with elevation of serum AP and  $\gamma$ GT to disclose intrahepatic or extrahepatic bile duct dilatation (see above) or focal liver lesions. There are no specific features of PBC on ultrasound; in particular the biliary tree appears normal. Ultrasound findings in advanced PBC resemble those seen in other forms of cirrhosis.

## Recommendations

1. A diagnosis of PBC can be made with confidence in adult patients with otherwise unexplained elevation of AP and presence of AMA ( $\geq 1:40$ ) and/or AMA type M2. A liver biopsy is not essential for the diagnosis of PBC in these patients, but allows activity and stage of the disease to be assessed (III/A1).
2. A liver biopsy is needed for the diagnosis of PBC in the absence of PBC specific antibodies. A liver biopsy may also be helpful in the presence of disproportionately elevated serum transaminases and/or serum IgG levels to identify additional or alternative processes (III/C1).

3. AMA-positive individuals with normal serum liver tests should be followed with annual reassessment of biochemical markers of cholestasis (III/C2).

## 3.2. Treatment of PBC

### 3.2.1. Ursodeoxycholic acid (UDCA)

Over the past two decades, increasing evidence has accumulated indicating that ursodeoxycholic acid (UDCA; 13–15 mg/kg/d) is the treatment of choice for patients with PBC based on placebo-controlled trials and more recent long-term case-control studies. UDCA has been demonstrated to exert anticholestatic effects in various cholestatic disorders. Several potential mechanisms and sites of action of UDCA have been unraveled in clinical and experimental studies which might explain its beneficial effects. Their relative contribution to the anticholestatic action of UDCA might depend on the type of the cholestatic injury. In early-stage PBC, protection of injured cholangiocytes against the toxic effects of bile acids might prevail, and stimulation of impaired hepatocellular secretion by mainly posttranscriptional mechanisms including stimulation of synthesis, targeting and apical membrane insertion of key transporters might be relevant in more advanced cholestasis [12]. In addition, stimulation of ductular alkaline cholerisis and inhibition of bile acid-induced hepatocyte and cholangiocyte apoptosis can have a certain role for the beneficial effect of UDCA in PBC [12].

UDCA has been demonstrated to markedly decrease serum bilirubin, AP,  $\gamma$ GT, cholesterol and immunoglobulin M levels, and to ameliorate histological features in patients with PBC in comparison to placebo treatment [13–17] although no significant effects on fatigue or pruritus were observed in these large trials. Moreover, long-term treatment with UDCA delayed the histological progression of the disease in patients in whom treatment was started at an early stage [17,18]. Still, a clear-cut beneficial effect of UDCA on survival has not been shown in any of the studies mentioned above, probably due to the limited number of patients and the limited observation periods too short for a slowly progressing disease. A beneficial effect of UDCA on survival has only been demonstrated in a combined analysis of the raw data from the French, Canadian and Mayo cohorts followed up for 4 years [19]. In this analysis, UDCA treatment was associated with a significant reduction in the likelihood of liver transplantation or death. This benefit was seen in patients with moderate and severe disease but not in those with mild disease (serum bilirubin concentration  $<1.4$  mg/dL (24  $\mu$ mol/L), stage I or II histologic change) in whom progression to end-stage disease did not occur during the 4-year period of observation [19].

The affirmative results on survival have been challenged by meta-analyses which included a majority of

studies of up to two years' duration and trials using UDCA doses which are today known to be ineffective [20,21]. Inclusion of trials which have a duration of three months to two years for a disease with an estimated duration of one to two decades without intervention may be suited to analyze biochemical effects of medical treatment, but certainly carries a risk to dilute the information needed for a well-based survival analysis. Therefore, it was not surprising that meta-analyses which excluded studies of short duration (less than 24 months) and those that used an ineffective dose of UDCA (less than 10 mg/kg/d) concluded that long-term UDCA significantly improved transplant-free survival and delayed histologic progression in early-stage patients [22,23].

Recent reports have demonstrated the favorable effects of UDCA on long-term survival in patients with PBC receiving standard doses (13–15 mg/kg/d) [24] over 10–20 years. Treatment with UDCA led to a transplant-free survival similar to that of a healthy control population matched for age and gender in patients with early-stage disease [25,26] and to improved survival in comparison to the estimated survival at the start of treatment as calculated by the Mayo risk score for PBC [25–27]. Interestingly, a “good biochemical response” to UDCA defined as a decrease in AP >40% of pretreatment levels or normalization at one year (“Barcelona criteria”) was associated with an excellent 95% transplant-free survival at 14 years of follow-up, similar to that predicted for the standardized population [27]. The prognostic impact of the “Barcelona criteria” was confirmed in a large independent cohort of PBC patients for which a serum bilirubin  $\leq 1$  mg/dL (17  $\mu$ mol/L), AP  $\leq 3 \times$  ULN, and AST  $\leq 2 \times$  ULN (“Paris criteria”) after one year of treatment even better identified those with a good long-term prognosis of a 90% (vs. 51%) ten year transplant-free survival [28]. Thus, additional therapeutic options for those patients failing to reach a “good biochemical response” under UDCA are warranted.

### 3.2.2. Corticosteroids and other immunosuppressive agents

Prednisolone improved serum liver tests and histological features, but markedly worsened bone mineral density in patients with PBC [29] prohibiting its long-term use in PBC. In combination with UDCA (10 mg/kg/d), prednisolone (10 mg/d, 9 months) exerted beneficial effects on various features of liver histology in early-stage PBC in comparison to UDCA alone [30].

Budesonide in combination with UDCA showed favorable results on biochemical and histological parameters in early-stage disease [31,32], but not late-stage disease [33,34]. Studies with a longer follow-up using the combination of budesonide and UDCA in patients with early-stage disease not adequately responding to UDCA alone are warranted to confirm its safety and its effect on postponing or preventing the need for liver transplanta-

tion. Development of portal vein thrombosis probably related to short-term budesonide administration was reported in stage 4 patients with portal hypertension [34]. Thus, budesonide should not be administered to cirrhotic patients.

Other immunosuppressive agents like azathioprine [35], cyclosporine A [36], methotrexate [37–39], chlorambucil [40] and mycophenolate mofetil [41] proved to be marginally effective, ineffective or potentially harmful during long-term administration and cannot be recommended for standard treatment in PBC.

### 3.2.3. Anti-fibrotic agents

Colchicine was inferior to UDCA in the treatment of PBC [42] and did not, when combined with UDCA in comparison to UDCA alone [43], significantly improve symptoms, serum liver tests, serum markers of fibrosis, or histological features. Thus, addition of colchicine to UDCA currently cannot be recommended in the treatment of PBC.

D-Penicillamine is not effective in PBC and can be associated with severe side effects [44,45].

### 3.2.4. Other drugs

Malotilate [46], thalidomide [47], silymarin [48] and atorvastatin [49] were not effective in the treatment of PBC. Sulindac [50] and the peroxisome proliferator-activated receptor  $\alpha$  (PPAR $\alpha$ ) agonist, bezafibrate [51] improved some serum liver tests in limited groups of patients with an incomplete response to UDCA, and bezafibrate deserves further studies. Tamoxifen [52] decreased AP levels in two women who were taking it after surgery for breast cancer.

Antiretroviral strategies have also been tested in PBC: Lamivudine alone or in combination with zidovudine (Combivir) was associated with minor clinical and biochemical effects. Combivir was also associated with improvement of some histological features, but this finding needs confirmation in randomized studies [53].

### 3.2.5. Liver transplantation

Liver transplantation has dramatically improved survival in patients with late-stage PBC. Indications are not different from those of patients with other etiologies of liver failure [54]: decompensated cirrhosis with an unacceptable quality of life or anticipated death within a year due to treatment-resistant ascites and spontaneous bacterial peritonitis, recurrent variceal bleeding, encephalopathy or hepatocellular carcinoma. Severe, treatment-resistant pruritus may merit consideration for transplantation. Patients should be referred to a liver transplant center for assessment when their bilirubin approaches 6 mg/dL (103  $\mu$ mol/L), the Mayo risk score is  $\geq 7,8$ , and the MELD score is  $>12$  at the latest.

Survival rates above 90% and 80–85% at one and five years, respectively, have been reported by many centers

[55]. Most patients have no signs of liver disease after orthotopic liver transplantation, but their antimitochondrial antibody status does not change. The disease recurs with a calculated weighted disease recurrence of 18% [56], but rarely is associated with graft failure [54].

### Recommendations

1. Patients with PBC, including those with asymptomatic disease, should be treated with UDCA (13–15 mg/kg/d) (I/A1) on a long-term basis (II-2/B1).
2. Favorable long-term effects of UDCA are observed in patients with early disease and in those with good biochemical response (II-2/B1), which should be assessed after one year. A good biochemical response after one year of UDCA treatment is currently defined by a serum bilirubin  $\leq 1$  mg/dL (17  $\mu$ mol/L), AP  $\leq 3 \times$  ULN and AST  $\leq 2 \times$  ULN (“Paris criteria”) or by a decrease of 40% or normalization of serum AP (“Barcelona criteria”) (II-2/B1).
3. There is currently no consensus on how to treat patients with a suboptimal biochemical response to UDCA. One suggested approach is the combination of UDCA and budesonide (6–9 mg/d) in non-cirrhotic patients (stages 1–3) (III/C2). Further studies of this and other combination regimes should be a priority.
4. Liver transplantation should be strongly considered in patients with advanced disease as reflected by serum bilirubin exceeding 6 mg/dL (103  $\mu$ mol/L) or decompensated cirrhosis with an unacceptable quality of life or anticipated death within a year due to treatment-resistant ascites and spontaneous bacterial peritonitis, recurrent variceal bleeding, encephalopathy or hepatocellular carcinoma (II-2/A1).

## 4. PBC–AIH overlap syndrome

Primary biliary cirrhosis (PBC) and autoimmune hepatitis (AIH) are classically viewed as distinct liver diseases. However, patients presenting with clinical, biochemical, serological, and/or histological features reminiscent of both diseases, either simultaneously or consecutively have been repeatedly recognized. The ill-defined term “overlap syndrome” is used to describe these settings [57–60]. The pathogenesis of PBC–AIH overlap syndrome is debated and it remains unclear whether this syndrome forms a distinct entity or a variant of PBC or AIH. Different pathophysiological mechanisms have been discussed: (i) a pure coincidence of two independent autoimmune diseases; (ii) a different genetic background which determines the clinical, biochemical and histological appearance of one autoimmune disease entity; and (iii) a representation of the middle of a continuous spectrum of two autoimmune diseases [59,60].

### 4.1. Diagnosis

Standardization of diagnostic criteria for PBC–AIH overlap syndrome has not been achieved so far, and “overlap syndrome” is a much overused descriptive term in hepatology [61]. Diagnosis of PBC and AIH is based on the combination of biochemical, serological and histological features. However, no individual test shows absolute specificity and much depends on the relative weighting of individual diagnostic criteria, and the cut-off levels of continuous variables considered representative for one or another condition [59]. The 1999 scoring system, established by the International Autoimmune Hepatitis Group (IAIHG) for research purposes, comprises characteristic features of AIH and provides support for diagnosing AIH [62]. However, applicability of this scoring system remains questionable in this specific setting since a score of “definite” AIH can be only observed in the very few patients with characteristic overlap syndrome whereas nearly 20% of PBC subjects will be classified with “probable” AIH overlap [61,63,64]. The simplified diagnostic score recently proposed by the IAIHG has not been validated yet in patients with suspected PBC–AIH overlap syndrome [65]. To differentiate PBC from PBC–AIH overlap syndrome, another diagnostic score has been established but the usefulness of this rather complex score needs confirmation by cross-evaluation prior to introduction to the clinic [66]. Because of the limited applicability of the different diagnostic scores, another approach based on the major characteristics of PBC and AIH has been proposed and requires the presence of at least 2 of the 3 accepted criteria of both diseases for diagnosing PBC–AIH overlap syndrome (Table 4) [57] whereby histologic evidence of moderate to severe lymphocytic piecemeal necrosis (interface hepatitis) is mandatory.

In addition to cases with simultaneous characteristics of PBC and AIH, which is the most frequent mode of presentation, transitions from PBC to AIH or *vice-versa* have been described and termed “sequential syndromes”

**Table 4**  
Diagnostic criteria of PBC–AIH overlap syndrome.

#### *PBC criteria*

1. AP  $> 2 \times$  ULN or  $\gamma$ GT  $> 5 \times$  ULN
2. AMA  $\geq 1:40$
3. Liver biopsy specimen showing florid bile duct lesions

#### *AIH criteria*

1. ALT  $> 5 \times$  ULN
2. IgG  $> 2 \times$  ULN or a positive test for anti-smooth muscle antibodies (ASMA)
3. Liver biopsy showing moderate or severe periportal or periseptal lymphocytic piecemeal necrosis

Diagnostic criteria of PBC–AIH overlap syndrome of which at least 2 of 3 accepted criteria for PBC and AIH, respectively, should be present (proposed by Chazouilleres et al. [57]). Histologic evidence of moderate to severe lymphocytic piecemeal necrosis (interface hepatitis) is mandatory for the diagnosis.



or consecutive forms [67]. Occurrence of superimposed AIH cannot be predicted from baseline characteristics and initial response to UDCA therapy in PBC patients [67]. Lastly, overlap of AMA-negative PBC with AIH has also been reported [57].

Precise prevalence of PBC–AIH overlap syndrome is unknown but approximately 10% of adults with AIH or PBC may belong in this overlap category [67–69]. Patients with PBC–AIH overlap syndrome might have a more severe disease with worse clinical outcomes compared to patients with PBC alone [70]. This emphasizes the notion that overlap syndrome should always be considered once PBC has been diagnosed [68].

#### 4.2. Treatment

The low prevalence of PBC–AIH overlap syndrome has made controlled therapeutic trials impossible in these patients. Thus, therapeutic recommendations rely on the experience in the treatment of either PBC or AIH, and on retrospective, non-randomized studies. Whether PBC–AIH overlap syndrome requires immunosuppressive therapy in addition to UDCA is a debated issue. Under UDCA therapy, biochemical response at 24 months and survival in one cohort of 12 strictly defined PBC–AIH overlap syndrome patients were similar to 159 patients with “pure” PBC [71]. However, adjunction of immunosuppressive therapy was required in most patients of other cohorts to obtain a complete biochemical response [57,58]. In the largest long-term follow-up study, 17 strictly defined patients [64] received UDCA alone or UDCA in combination with immunosuppressors and were followed for 7.5 years. In the 11 patients treated with UDCA alone, biochemical response in terms of AIH features (ALT  $<2 \times$  ULN and IgG  $<16$  g/L) was observed in only 3 patients whereas the 8 others were non-responders with increased fibrosis in 4. Overall, fibrosis progression in non-cirrhotic patients occurred more frequently under UDCA monotherapy (4/8) than under combined therapy (0/6) ( $p = 0.04$ ). These results strongly suggest that combined therapy (UDCA and corticosteroids) is the best therapeutic option in most patients with strictly defined simultaneous PBC–AIH overlap syndrome. An alternative approach is to start with UDCA alone and to add corticosteroids if UDCA therapy does not induce an adequate biochemical response in an appropriate time span (e.g., 3 months) [69]. Prednisone has been used at an initial dose of 0.5 mg/kg/d and should be progressively tapered once ALT levels show a response [64]. Budesonide is a promising treatment option for patients with AIH and has also been used with success in some patients with PBC–AIH overlap syndrome [72]. The role of other immunosuppressants, e.g., azathioprine, in the long-term management of these patients is unclear, but its successful use in AIH makes azathioprine an attrac-

tive alternative to corticosteroids for long-term immunosuppressive therapy. Interestingly, by comparison with typical AIH, it has been suggested that doses of immunosuppressants could be lower and rate of successful withdrawal higher [64]. For corticosteroid-resistant patients, a beneficial effect of other immunosuppressants such as cyclosporine A has been reported [73].

In UDCA-treated PBC patients developing AIH (“sequential” overlap), use of immunosuppressive treatment is mandatory [67].

#### Recommendations

1. Standardization of diagnostic criteria for PBC–AIH overlap syndrome has not been achieved. Strict diagnostic criteria as shown in Table 4 provide a useful diagnostic template (III/C2).
2. PBC–AIH overlap syndrome should always be considered once PBC has been diagnosed because of potential implications for therapy (III/C2).
3. Combined therapy with UDCA and corticosteroids is the recommended therapeutic option in patients with PBC–AIH overlap syndrome (III/C2). An alternative approach is to start with UDCA only and to add corticosteroids if UDCA therapy has not induced an adequate biochemical response in an appropriate time span (3 months) (III/C2). Steroid sparing agents should be considered in patients requiring long-term immunosuppression (III/C2).

#### 5. Primary sclerosing cholangitis

Primary sclerosing cholangitis (PSC) is a chronic, cholestatic liver disease that is characterized by an inflammatory and fibrotic process affecting both intra- and extrahepatic bile ducts [74]. The disease leads to irregular bile duct obliteration, including formation of multifocal bile duct strictures. PSC is a progressive disorder that eventually develops into liver cirrhosis and liver failure. The etiology of PSC is unknown, but there is evidence that genetic susceptibility factors are involved [75]. The male to female ratio is approximately 2:1. PSC can be diagnosed in children as well as in the elderly, but mean age at diagnosis is around 40 years. Up to 80% of PSC patients have concomitant inflammatory bowel disease (IBD) that in the majority of cases is diagnosed as ulcerative colitis (UC). Thus, the “typical” PSC patient is a young to middle-aged man with IBD who presents with biochemical and/or clinical signs of a cholestatic liver disease.

##### 5.1. Diagnosis of PSC

A diagnosis of PSC is made in patients with elevated serum markers of cholestasis (AP,  $\gamma$ GT) not otherwise

explained, when magnetic resonance cholangiopancreatography (MRCP) or endoscopic cholangiopancreatography (ERCP) show characteristic bile duct changes with multifocal strictures and segmental dilatations, and causes of secondary sclerosing cholangitis [76] and other cholestatic disorders are excluded. Patients who present with clinical, biochemical and histological features compatible with PSC, but have a normal cholangiogram, are classified as small duct PSC.

#### 5.1.1. Signs and symptoms

About 50% of PSC patients are symptomatic at first presentation. Typical symptoms include pruritus, pain in the right upper abdominal quadrant, fatigue, weight loss, and episodes of fever and chills, which are reported in a variable number of patients [77]. Symptoms of liver cirrhosis and portal hypertension with ascites and variceal hemorrhage are more rarely reported at diagnosis in PSC. Hepatomegaly and splenomegaly are the most frequent findings at clinical examination at the time of diagnosis in PSC. Osteopenic bone disease is a complication of advanced PSC, although less frequent than that reported in PBC. Fat malabsorption with steatorrhea and malabsorption of fat-soluble vitamins occur only with prolonged cholestasis.

#### 5.1.2. Biochemical tests

Elevation of serum AP is the most common biochemical abnormality in PSC [77–79]. However, a normal AP activity should not preclude further steps to diagnose PSC if suspected on clinical basis. Serum aminotransferase levels are elevated at diagnosis in the majority of patients, typically to levels 2–3 times upper limits of normal, but normal levels are also observed. Serum bilirubin levels are normal at diagnosis in up to 70% of patients. Elevated levels of IgG have been noted in 61% of patients, most often to a level up to 1.5 times upper limit of normal [80]. In one retrospectively studied cohort, 9% of PSC patients were reported with slightly elevated IgG4 levels, but total IgG was not reported in these patients. It remains unclear whether some of these patients suffered from IgG4-associated cholangitis (IAC) rather than PSC [81]. Increased IgM levels have been reported in up to 45% of PSC cases [78].

#### 5.1.3. Autoantibodies

A variety of autoantibodies have been detected in PSC [82]. The autoantibodies most frequently reported are perinuclear antineutrophil cytoplasmic antibodies (pANCA) (26–94%), antinuclear antibodies (ANA) (8–77%), and smooth muscle antibodies (SMA) (0–83%) [82]. The pANCA pattern in PSC is “atypical”, as the putative antigen is located in the nucleus rather than in the cytoplasm. Atypical pANCA is frequently present in UC and AIH, and specificity in the diagnosis of PSC is low. Positive titres of ANA and SMA also are un-

cific. A routine autoantibody screening is not required to establish a diagnosis of PSC. Analysis of ANA and SMA may be relevant in a subgroup of patients to support a suspicion of “autoimmune” features that may have therapeutic implications (see “PSC–AIH overlap syndrome”).

#### 5.1.4. Liver biopsy

Liver histological findings may support a diagnosis of PSC, but they are non-specific and may show considerable variation. PSC has been described to progress through four stages. The initial changes (stage 1, portal stage) are limited to the portal tracts with features including portal oedema, mild portal hepatitis, a non-destructive cholangitis with infiltration of lymphocytes in the bile ducts, and ductular proliferation. Periductal fibrosis and fibrous-obliterative cholangitis may be present. In stage 2 (periportal stage), the lesion extends to involve periportal fibrosis, sometimes with interphase hepatitis. Portal tracts are often enlarged. In stage 3 (septal stage) there is development of bridging fibrous septa, while bile ducts degenerate and disappear. Stage 4 is characterized by cirrhosis [83]. Periductal concentric fibrosis is considered highly suggestive of PSC, but this finding is relatively infrequent in needle biopsies in PSC and may also be associated with other conditions. Histological changes can be very subtle, and a liver biopsy may even appear normal because of sampling variability and since the liver is not uniformly involved. In PSC patients with relatively high serum aminotransferase levels, particularly in combination with positive ANA and/or SMA titres and markedly elevated IgG levels, a liver biopsy may be indicated to disclose features of a PSC–AIH overlap syndrome.

#### 5.1.5. Imaging

*Ultrasonography (US):* In PSC, US is not diagnostic and often normal, but bile duct wall thickening and/or focal bile duct dilatations may be observed by experts. One or more gallbladder abnormalities, including wall thickening, gallbladder enlargement [84], gallstones, cholecystitis, and mass lesions, have been reported on the basis of US or cholangiography in up to 41% of PSC patients [85].

*Cholangiography:* A detailed cholangiographic assessment of the biliary tree is essential in making a diagnosis of PSC [86]. Efforts should be made to adequately visualize also the intrahepatic ducts to avoid false-negative results by overlooking subtle changes. The characteristic cholangiographic findings of PSC include mural irregularities and diffusely distributed multifocal, short, annular strictures alternating with normal or slightly dilated segments producing a “beaded” pattern [87]. Sometimes outpouchings have a diverticular appearance [87]. With more advanced disease, long, confluent strictures may be seen [87]. In the majority of cases, both the intra- and

extrahepatic bile ducts are involved. A variable proportion of patients (<25%) is described to have isolated intrahepatic disease, whereas lesions confined to the extrahepatic ducts are rarely observed (usually <5%) and should only be diagnosed in the presence of adequate filling of the intrahepatic ducts. Since intrahepatic bile duct abnormalities can also be seen in other chronic liver diseases, one must be cautious when diagnosing PSC in the presence of intrahepatic changes only. The gallbladder and cystic duct are involved in some cases, and abnormalities of the pancreatic duct resembling those of chronic pancreatitis have been noted in a variable number of PSC patients [87].

Endoscopic retrograde cholangiopancreatography (ERCP) has been the gold standard in diagnosing PSC [86,87], but ERCP is associated with complications such as pancreatitis and sepsis [88]. Clinicians may be reluctant to proceed with an ERCP in the assessment of cholestasis, and therefore, PSC most likely has been an underdiagnosed condition. Magnetic resonance cholangiopancreatography (MRCP) is a non-invasive method that in experienced centres is now generally accepted as a primary diagnostic modality in cases of suspected PSC. Studies comparing ERCP and MRCP have shown similar diagnostic accuracy, although the depiction of bile ducts may be poorer with MRCP than with ERCP [89]. Sensitivity and specificity of MRCP has been  $\geq 80\%$  and  $\geq 87\%$ , respectively, for the diagnosis of PSC [89,90]. MRCP is superior in visualizing bile ducts proximal to duct obstructions. The method can also reveal changes within the bile duct walls and pathologies in the liver parenchyma as well as in other organs. However, cases with mild PSC changes without bile duct dilatation may be missed by MRCP and one should therefore be cautious to exclude early PSC on the basis of a normal MRCP. Thus, diagnostic ERCP still has a role in equivocal cases. The main role of ERCP, however, lies in therapeutic procedures and in diagnostic purposes like cytology sampling in PSC.

#### 5.1.6. Small duct PSC

The term small duct PSC refers to a disease entity which is characterized by clinical, biochemical, and histological features compatible with PSC, but having a normal cholangiogram [91]. One report has restricted the diagnosis of small duct PSC to patients with concomitant IBD [92], whereas IBD has only been present in a proportion (50–88%) of cases in other studies [93,94]. These studies carry the risk to include patients with other cholangiopathies such as ABCB4 deficiency which cause histological features compatible with small duct PSC [95]. A high-quality cholangiogram is mandatory in order to exclude PSC with isolated intrahepatic distribution. One future approach for the diagnosis of small duct PSC is to accept a negative MRC in patients with concomitant IBD, but require a normal ERCP and

a negative mutation analysis of ABCB4 in patients without IBD. Diagnostic criteria in small duct PSC are however still being discussed.

#### 5.1.7. PSC in children

Criteria for diagnosis of PSC in adults also apply to children. Of note, levels of serum AP activity were observed within the normal range for the age group in up to 47% of cases [96,97]. Patients with normal AP usually had elevated  $\gamma$ GT activity [96,97]. Presentation of PSC in children is frequently reported with features similar to those of autoimmune hepatitis, including high IgG concentrations, positive ANA and/or SMA titers and interphase hepatitis in the liver biopsy [96–98].

#### 5.1.8. Differential diagnosis of PSC versus secondary forms of sclerosing cholangitis

Before the diagnosis of PSC can be settled, causes of secondary sclerosing cholangitis such as previous biliary surgery, cholangiolithiasis and disorders mimicking PSC such as carcinoma of the bile ducts have to be excluded although cholangiolithiasis and cholangiocarcinoma may also be the consequence of PSC [76]. Clinical and cholangiographic findings resembling those of PSC have most commonly been described in relation to intraductal stone disease, surgical trauma from cholecystectomy, abdominal injury, intra-arterial chemotherapy, and recurrent pancreatitis [76]. A variety of other conditions have also been associated with features imitating those of PSC, including IgG4-associated cholangitis/autoimmune pancreatitis (see below), hepatic inflammatory pseudotumor, eosinophilic cholangitis, mast cell cholangiopathy, portal hypertensive biliopathy, AIDS cholangiopathy, recurrent pyogenic cholangitis, ischemic cholangitis, as well as others [76]. Differentiating between primary and secondary sclerosing cholangitis may be particularly difficult since PSC patients themselves may have undergone bile duct surgery or have concomitant intraductal stone disease or even cholangiocarcinoma (CCA). Factors like clinical history, the distribution of the cholangiographic abnormalities, as well as the presence of concomitant IBD, have to be taken into account when determining whether a pathological cholangiogram is due to PSC or secondary to a benign or malignant bile duct stricture without PSC [76].

### Recommendations

1. A diagnosis of PSC is made in patients with biochemical markers of cholestasis not otherwise explained, when MRCP shows typical findings and causes of secondary sclerosing cholangitis are excluded (II-2/B1). A liver biopsy is not essential for the diagnosis of

- PSC in these patients, but allows activity and staging of the disease to be assessed.
2. A liver biopsy should be performed to diagnose small duct PSC if high-quality MRCP is normal, (III/C2). A liver biopsy may also be helpful in the presence of disproportionately elevated serum transaminases and/or serum IgG levels to identify additional or alternative processes (III/C1).
  3. ERCP can be considered
    - (i) If high-quality MRCP is uncertain (III/C2): the diagnosis of PSC is made in the case of typical ERCP findings.
    - (ii) In patients with IBD with normal high-quality MRCP but high suspicion for PSC (III/C2).

## 5.2. Follow-up of PSC

### 5.2.1. Inflammatory bowel disease and risk of colon cancer

PSC is strongly associated with IBD, with a prevalence of IBD in Western countries commonly in the range of 60–80% [77,78] whereas in a recent report on 391 Japanese patients only 125 had a history of concomitant IBD [99]. UC accounts for the majority (80%) of IBD cases in PSC, while around 10% have Crohn's disease and another 10% are classified as indeterminate colitis [100]. IBD can be diagnosed at any time during the course of PSC, but in a majority of cases IBD precedes PSC. Since the colitis in PSC characteristically is mild and sometimes even asymptomatic, colonoscopy with biopsies is recommended as part of the routine work-up in a patient diagnosed with PSC. A diagnosis of IBD has implications for follow-up and dysplasia/cancer surveillance as patients with UC and PSC have a higher risk of dysplasia and colon cancer than patients with UC only [101,102]. Compared to UC patients without PSC, the colitis in PSC more frequently is a pancolitis (87% vs. 54%), with backwash ileitis (51% vs. 7%), and rectal sparing (52% vs. 6%) [100]. Patients with PSC and Crohn's disease characteristically only have colonic involvement. We recommend that PSC patients with colitis are enrolled in a surveillance program with annual colonoscopy with biopsies from the time of diagnosis of PSC [102].

### 5.2.2. Hepatobiliary malignancies in PSC

PSC is associated with an increased risk of hepatobiliary malignancies, in particular cholangiocarcinoma (CCA). In a large cohort of 604 Swedish PSC patients followed for (median) 5.7 years, hepatobiliary malignancies (CCA, hepatocellular carcinoma (HCC), and gallbladder carcinoma) were observed in 13.3%, corresponding to a risk 161 times that of the general population [103]. CCA is by far the most common hepatobiliary malignancy in PSC, with a cumulative life-time

incidence of 10–15% [104], whereas gallbladder carcinoma [85] and HCC [105] are observed in up to 2% of PSC patients, each. Up to 50% of CCA are diagnosed within the first year of diagnosis of PSC. After the first year, the yearly incidence rate is 0.5–1.5% [104]. Although factors like older age, alcohol consumption and smoking, long duration of IBD before diagnosis of PSC, and a history of colorectal malignancy, have been associated with an increased risk of CCA in PSC, no clinically useful prognostic variables have been identified so far. Possible genetic markers should be further explored [75]. The symptoms of CCA complicating PSC may be very difficult to differentiate from those of PSC without concomitant malignancy, but awareness of CCA must in particular be raised in cases of rapid clinical deterioration.

Median levels of the serum tumour marker carbohydrate antigen 19-9 (CA 19-9) are significantly higher in PSC patients with CCA than in those without [104], but in the individual case CA 19-9 cannot be relied upon in the differential diagnosis between PSC with and without CCA [104]. Distinguishing benign from malignant changes in PSC by imaging modalities like US, CT, MRCP/MRI as well as ERCP, is equally difficult [104,106]. Serum CA 19-9 combined with cross-sectional liver imaging may be useful as a screening strategy [107], but further validation is needed. Whether dynamic (<sup>18</sup>F)-fluoro-deoxy-D-glucose positron emission tomography (FDG-PET) [108] is more effective when combined with CT or MRI, needs to be shown. Brush cytology sampling, and biopsy when feasible, during ERCP adds to the diagnostic accuracy of CCA in PSC [104,107,109], but methodological refinement including validation of digital image analysis (DIA) and fluorescence *in situ* hybridization (FISH) of cell samples [107] is needed.

Gallbladder mass lesions in PSC frequently (>50%) represent adenocarcinomas independently of their size [85]. Cholecystectomy is recommended in PSC patients with a gallbladder mass even <1 cm in diameter [85]. The risk for pancreatic carcinoma was 14-fold increased in a Swedish cohort of PSC patients in comparison to a matched-control population [103], but its incidence in PSC is markedly lower than that of hepatobiliary malignancies, and regular screening strategies are, therefore, not recommended at present.

## Recommendations

1. Total colonoscopy with biopsies should be performed in patients in whom the diagnosis of PSC has been established without known IBD (III/C1) and should be repeated annually (or every 1–2 years in individualized patients) in PSC patients with colitis from the time of diagnosis of PSC (III/C1).
2. Annual abdominal ultrasonography should be considered for gallbladder abnormalities (III/C2).

3. There is at present no biochemical marker or imaging modality which can be recommended for early detection of cholangiocarcinoma. ERCP with brush cytology (and/or biopsy) sampling should be carried out when clinically indicated (III/C2).

### 5.3. Treatment of PSC

#### 5.3.1. Ursodeoxycholic acid (UDCA)

**UDCA and disease progression:** UDCA is an effective treatment of primary biliary cirrhosis (PBC) as outlined above (2.2.1). UDCA has, therefore, also been investigated as a potential candidate for the treatment of PSC. Small pilot trials of UDCA in the early 1990's demonstrated biochemical and in some cases histological improvement in PSC patients using doses of 10–15 mg/kg/day [110–113]. A more substantial trial was published by Lindor in 1997 [114], recruiting 105 patients in a double-blind placebo-controlled trial of 13–15 mg/kg of UDCA for 2 years. The results indicated improvement in serum liver tests but not in symptoms and, most importantly, no improvement in liver histology as evaluated by disease stage [114]. Higher doses of UDCA were then studied on the grounds that larger doses might be necessary to provide sufficient enrichment of the bile acid pool in the context of cholestasis, and that these doses might also enhance the potential immunomodulatory effect of the drug. Studies using 20–25 mg/kg/day demonstrated significant improvements in the histological grade of liver fibrosis and the cholangiographic appearances of PSC, as well as the expected biochemical improvement [115]. A shorter, open-label trial using 25–30 mg/kg/day showed a significant improvement in projected survival using the Mayo risk score, but no direct measurement of the progression of the disease, such as liver biopsy or cholangiography was undertaken. Confirmatory results were obtained in a 2-year dose ranging pilot study of 30 patients in which the low dose (10 mg/kg/d) and the standard dose (20 mg/kg/d) tended to improve and the high dose (30 mg/kg/d) significantly improved projected survival [116].

The Scandinavian UDCA trial deserves major credit for recruiting the largest group of PSC patients ( $n = 219$ ) for the longest treatment period (5 years) ever studied using a dose of 17–23 mg/kg/day. It demonstrated a trend towards increased survival in the UDCA-treated group when compared with placebo [117]. But despite the relatively large number of patients recruited, it was still insufficiently powered to produce a statistically significant result. In comparison to other studies, the biochemical response was unexpectedly poor in this trial which prompted questions about adequate compliance in a part of the study population. Recently, a multicentre study using high doses of 28–30 mg/kg/d of UDCA in 150 PSC patients over 5 years has been

aborted because of an enhanced risk in the UDCA treatment group to reach primary endpoints such as liver transplantation or development of varices in more advanced disease while biochemical features improved in the whole UDCA group [118]. Thus, the role for UDCA in slowing the progression of PSC-related liver disease is as yet unclear and high dose UDCA may be harmful in late-stage disease.

**UDCA and chemoprevention:** Recent work has suggested that UDCA may have a role in the prevention of colonic neoplasia in patients with PSC associated with underlying IBD. Experimental studies *in vitro* and *in vivo* had suggested that UDCA might prevent development of colon carcinoma. A cross-sectional study of 59 PSC patients with ulcerative colitis (UC) undergoing colonoscopic surveillance found a significantly reduced risk of colonic dysplasia in patients taking UDCA although in comparison to an exceptionally high rate of dysplasia in the control group [119]. A historical cohort study compared 28 PSC patients under UDCA treatment with UC to 92 PSC patients with UC not treated with UDCA [120] and found a trend towards a lower risk of colonic dysplasia and neoplasia under UDCA treatment (adjusted relative risk 0.59, 95% CI 0.26–1.36,  $p = 0.17$ ) and a lower mortality (adjusted relative risk 0.44, 95% CI 0.22–0.90,  $p = 0.02$ ) [120]. A third study followed 52 patients with PSC and UC for 355 patient-years who participated in a randomized, placebo-controlled UDCA trial showing a significant reduction to 0.26 (95% CI 0.06–0.92,  $p = 0.003$ ) in UDCA-treated patients in the relative risk of developing colorectal dysplasia or carcinoma [121].

Limited evidence for a beneficial effect of UDCA on the risk to develop CCA comes from observational studies. The Scandinavian and American randomized, placebo-controlled UDCA trials with 219 and 150 PSC patients, respectively, did not observe a difference between UDCA- and placebo-treated patients regarding CCA development [117]. A German cohort study including 150 patients followed for a median of 6.4 years under UDCA treatment found CCA in 5 patients (3.3%), which represents about half the expected incidence of CCA in PSC [122]. A Scandinavian study of 255 PSC patients listed for liver transplantation over a period of 11 years revealed lack of ursodeoxycholic acid treatment as an independent risk factor for the development of hepatobiliary malignancy [123].

#### 5.3.2. Immunosuppressive and other agents

Corticosteroids and other immunosuppressants have not demonstrated improvement in disease activity or outcome of PSC. Small randomized, placebo-controlled or pilot trials have investigated the role of agents with immunosuppressive potency like prednisolone, budesonide, azathioprine, cyclosporine, methotrexate,

mycophenolate, and tacrolimus, agents with TNF $\alpha$  antagonizing effects like pentoxifyllin, etanercept and anti-TNF monoclonal antibodies and anti-fibrotic agents like colchicine, penicillamine, or pirfenidone. There is no evidence that these drugs are effective and, therefore, none can be recommended for classic PSC. These drugs may well have a role in the context of a PSC–AIH overlap syndrome (see below) since pediatric patients and those with evidence of a PSC–AIH overlap syndrome are more likely to respond to immunosuppressive treatment [59,60,98]. A retrospective study in adults also suggested a beneficial role of steroids in a subgroup with AIH overlap features [124].

### 5.3.3. ERCP and endoscopic therapy

Diagnostic ERCP has been the procedure of choice for suspected PSC in the past, but is associated with significant risks including pancreatitis and cholangitis [125,126]. Whilst a low complication rate was found in patients undergoing ‘diagnostic’ ERCP, the complication rate increased up to 14% when interventions such as balloon dilatation, endoscopic sphincterotomy and stenting were performed [4,127].

Dominant bile duct strictures have been defined as stenoses <1.5 mm in diameter in the common bile duct and <1 mm in the right and left hepatic duct [128]. The prevalence of dominant bile duct strictures in large duct PSC is variously reported as being 10–50%. Studies in animals and humans have suggested that decompression of biliary obstruction may prevent further damage and can reverse fibrotic liver disease [129]. Endoscopic treatment of biliary strictures often improves liver biochemistry and pruritus and may reduce the risk of recurrent cholangitis. Therefore, repeated endoscopic dilatation of dominant biliary strictures has been carried out in symptomatic patients [130–132]. Non-randomized studies comparing jaundice, cholangitis, transplantation and actuarial survival rates with estimates from prognostic models have suggested a trend towards a benefit of endoscopic intervention for dominant biliary strictures although patients also received UDCA [131,133]. In contrast, a Swedish study which compared liver biochemistry in those with and without dominant strictures suggested that variations in cholestasis and jaundice are a feature of PSC liver disease and not related to dilatation of dominant strictures [128]. The optimum method and frequency of dilatation of dominant strictures is unclear. The most widely used technique to facilitate biliary drainage has been plastic stent insertion with or without prior dilatation. The problem with this approach is that further ERCP’s are required to remove or replace the stent and there is a high rate of stent occlusion and/or cholangitis within 3 months of insertion. One study assessed the effectiveness and safety of short-term stenting (mean 9 days) resulting in improved outcome, particularly with

regard to cholangitis and stent occlusion rates [134]. The strategy of short-term stenting for 2–3 weeks is followed by some experienced centers. Other studies have compared the role of stenting with balloon dilatation, with similar efficacy and lower rates of complications such as cholangitis (18% vs. 50%) associated with balloon dilatation alone [135]. Multiple dilatations are usually required over months or years in order to maintain patency once dominant strictures are identified and treated, and not all strictures are amenable to endoscopic intervention. In these patients, careful consideration should be made regarding a conservative, radiological or surgical (including liver transplantation) approach to treatment.

### 5.3.4. Liver transplantation

Liver transplantation is the only therapy of late-stage PSC that can cure advanced disease. One and ten-year survival after liver transplantation has lately been above 90% and 80%, respectively, in experienced centers. Resection of the extrahepatic biliary tree and Roux-en-Y choledochojejunostomy are widely regarded as the method of choice for biliary reconstruction after liver transplantation in PSC [136]. Recurrence of PSC after liver transplantation has been reported at various rates up to a third of patients transplanted, but is difficult to define due to similarities in bile duct damage with ischemic type biliary lesions, infections, medication-induced injury, preservation injury, or chronic rejection [137]. In different cohorts, PSC recurrence was associated with steroid-resistant rejection, OKT3 use, preservation injury, ABO incompatibility, cytomegalovirus infection, male sex, or donor-recipient gender mismatch [138]. Colectomy prior to liver transplantation for advanced colitis or colon dysplasia protected against PSC recurrence as did the absence of ulcerative colitis [139].

## Recommendations

1. The available data base shows that UDCA (15–20 mg/d) improves serum liver tests and surrogate markers of prognosis (I/B1), but does not reveal a proven benefit on survival (III/C2). The limited data base does not yet allow a specific recommendation for the general use of UDCA in PSC.
2. Currently there is suggestive but limited evidence for the use of UDCA for chemoprevention of colorectal cancer in PSC (II-2/C2). UDCA may be particularly considered in high-risk groups such as those with a strong family history of colorectal cancer, previous colorectal neoplasia or longstanding extensive colitis (III/C2).
3. Corticosteroids and other immunosuppressants are not indicated for treatment of PSC in adults unless there is evidence of an overlap syndrome (III/C2).

4. Dominant bile duct strictures with significant cholestasis should be treated with biliary dilatation (II-2/B1). Biliary stent insertion should be reserved for cases where stricture dilatation and biliary drainage are unsatisfactory (III/C2). Prophylactic antibiotic coverage is recommended in this setting (III/C1).
5. Liver transplantation is recommended in patients with late-stage PSC (II-2/A1) and may be considered in patients with evidence of cholangiocyte dysplasia or severe recurrent bacterial cholangitis (III/C2).

## 6. PSC–AIH overlap syndrome

### 6.1. Diagnosis

PSC–AIH overlap syndrome is an ill-defined immune-mediated disorder which is predominantly found in children, adolescents and young adults [98,140–148]. Its characteristics include clinical, biochemical, and histologic features of AIH as summarized in the modified AIH score defined by an international group of experts for study purposes [62] and cholangiographic features typical of PSC [60]. Retrospective diagnosis of an overlap syndrome by use of the modified AIH score was established in 8% of 113 PSC patients from The Netherlands [149], and in 1.4% of 211 PSC patients from the U.S. (with somewhat incomplete data available for retrospective analysis) [150]. Prospective analysis of 41 consecutive PSC patients from Italy for the presence of: (i) a revised AIH score >15; (ii) ANA or ASMA antibodies present in a titre of at least 1:40; and (iii) liver histology with piecemeal necrosis, lymphocyte rosetting, and moderate or severe periportal or periseptal inflammation revealed a PSC–AIH overlap syndrome as defined by these criteria in 17% [151]. These patients were treated with UDCA (15–20 mg/kg daily), prednisolone (0.5 mg/kg daily, tapered to 10–15 mg/d) and 50–75 mg azathioprine with good biochemical response.

The largest case series reported so far consisted of 27 children with PSC–AIH overlap syndromes from England [98] out of 55 children with clinical, biochemical, and histological signs of AIH, followed prospectively for 16 years. Children and adolescents with PSC–AIH overlap syndrome more commonly suffered from IBD and more often were positive for atypical pANCA in serum than those with AIH only. Otherwise, they presented with similar signs and symptoms. Serum transaminases tend to be higher in AIH, but serum AP although mostly elevated in PSC, may be normal both in PSC–AIH overlap syndrome and AIH. Increasing awareness for the PSC–AIH overlap syndrome has led to the observation that AIH and PSC may be sequential in their occurrence, and this has been described in children [98] and adults [152]. Thus, in patients with AIH who become cholestatic and/or resistant to immunosuppression, PSC should be ruled out.

### 6.2. Therapy

UDCA is widely used in the treatment of PSC although long-term efficacy remains unproven so far [112–117]. UDCA has been used in combination with immunosuppressive regimens in PSC–AIH overlap syndrome [98,151]. A response to immunosuppressive therapy has been documented in children [98]. UDCA in combination with an immunosuppressive regimen might, therefore, be an adequate medical treatment for most patients with PSC–AIH overlap syndrome [151], although no data of controlled trials exist. Prognosis of PSC–AIH overlap syndrome was reported to be better than that of PSC [151], but worse than that of AIH [148]. Liver transplantation is indicated in end-stage disease.

## Recommendations

1. PSC–AIH overlap syndrome is an ill-defined immune-mediated disorder characterized by histological features of AIH and cholangiographic findings typical of PSC (III/C2).
2. Medical treatment of AIH–PSC overlap syndrome with UDCA and immunosuppressive therapy is recommended, but is not evidence-based due to lack of adequate studies (III/C2). Liver transplantation is the treatment of choice for end-stage disease (III/A1).

## 7. Immunoglobulin G4-associated cholangitis

### 7.1. Diagnosis

Immunoglobulin G4-associated cholangitis (IAC) is a recently described biliary disease of unknown etiology that presents with biochemical and cholangiographic features indistinguishable from PSC, frequently involves the extrahepatic bile ducts, responds to anti-inflammatory therapy, is often associated with autoimmune pancreatitis and other fibrosing conditions, and is characterized by elevated serum IgG4 and infiltration of IgG4-positive plasma cells in bile ducts and liver tissue [153–159]. In contrast to PSC, IAC is not associated with IBD. Preliminary data suggest that immunopathogenesis of IAC strikingly differs from other immune-mediated cholestatic liver diseases like PSC and PBC in that T helper 2 (Th2) and T regulatory (Treg) cytokines were markedly overexpressed in IAC patients [158]. In the largest cohorts of 53 and 17 IAC patients, respectively [159,157], median age at diagnosis of the mostly male patients (7/8) was around 60 years.

The diagnosis of IAC was recently proposed to be definitive if a patient with biliary stricture(s) in the intrahepatic, proximal extrahepatic and/or intrapancreatic bile ducts

- (i) has recently undergone pancreatic/biliary surgery or core biopsy of the pancreas showing diagnostic features of autoimmune pancreatitis (AIP)/IAC; or
- (ii) shows classical imaging findings of AIP and elevated IgG4; or
- (iii) fulfils two of the following criteria (elevated serum IgG4; suggestive pancreatic imaging findings; other organ manifestations including sclerosing sialadenitis, retroperitoneal fibrosis, or gastrointestinal involvement and abdominal lymphadenopathy with infiltration of IgG4-positive plasma cells; >10 IgG4-pos. plasma cells per high power field in bile duct biopsies) and shows an adequate response to a 4-week course of corticosteroid treatment to allow stent removal without relapse of obstructive cholestasis, to reach serum liver tests <2× ULN, and to present decreasing IgG4 and CA 19-9 [159].

Although not yet cross-validated in an independent cohort of IAC patients, this diagnostic recommendation may temporarily serve as a guideline for diagnosis of IAC.

## 7.2. Treatment

Immunosuppressive treatment has been shown to exert a marked effect on inflammatory activity of IAC, and complete long-term remission after three months of treatment has been reported. However, the extent of disease may affect the long-term response, and a retrospective analysis showed that patients with alterations of proximal extrahepatic and intrahepatic bile ducts are prone to a higher risk of relapse after stop of treatment than patients with distal bile duct strictures only [159]. Thus, corticosteroids are regarded as the initial treatment of choice in this disease, and azathioprine at doses up to 2 mg/kg/d should be considered in those with proximal and intrahepatic stenoses and those after relapse during/after corticosteroid therapy. Treatment duration of 3 months may be sufficient for some patients, but long-term maintenance therapy at low doses may be required when disease activity has not completely come to a standstill or has relapsed.

### Recommendations

1. IAC is a corticosteroid-responsive (II-2/C2) sclerosing cholangitis of unknown immunopathogenesis which, unlike PSC, affects mostly older patients and has a good long-term prognosis after adequate response to immunosuppressive treatment (II-2/C2).
2. The diagnosis of IAC is proposed to be made in patients with cholangiographic findings typical of sclerosing cholangitis on the basis of (i) histological features of autoimmune pancreatitis (AIP)/IAC or (ii) classical imaging findings of AIP and elevated

IgG4; or (iii) two diagnostic biochemical, histological and imaging criteria and an adequate response to a 4-week course of corticosteroid treatment to allow biliary stent removal without relapse of obstructive cholestasis, and to reach serum liver tests <2× ULN (III/C2).

3. Long-term treatment of IAC with corticosteroids and/or azathioprine may be needed after relapse or for inadequate response (III/C2).

## 8. Genetic cholestatic liver diseases

### 8.1. Cystic fibrosis-associated liver disease

Cystic fibrosis-associated liver disease (CFALD) was observed in up to 27% of patients with CF during long-term follow-up as defined by hepatomegaly, persistent elevation of at least two serum liver tests and abnormal findings on ultrasound [160] and may manifest as neonatal cholestasis, hepatic steatosis, focal or multilobular cirrhosis. Complications of CFALD represent today the second most frequent cause of disease-related death in patients with CF.

#### 8.1.1. Diagnosis

Diagnostic criteria for CFALD are not well defined. CF-related hepatomegaly is found in a third of CF patients and may be caused by CFALD or as a consequence of cor pulmonale with liver congestion. Serum liver tests (AP, ALT, AST, bilirubin) are recommended at yearly intervals in CF patients [161]. Elevation above 1.5× ULN of serum liver tests should induce control after 3–6 months and when persisting should prompt further investigations to more closely evaluate liver damage (prothrombin time, albumin) and exclude other causes of liver disease (e.g., drugs, toxins, infections, biliary atresia, gallstones, antitrypsin deficiency, autoimmune hepatitis, PSC or other causes of bile duct obstruction). Ultrasound may reveal signs of CFALD such as hepatomegaly or bile duct alterations [161]. Liver biopsy is controversially discussed due to the focal nature of fibrosis/cirrhosis in many cases.

#### 8.1.2. Therapy

No therapy of proven benefit for the long-term prognosis of CFALD exists. Optimization of nutritional state in cholestatic patients to avoid vitamin deficiency and malnutrition is recommended, but not of proven efficacy.

UDCA at doses of 20–30 mg/kg/d has been shown to consistently improve serum liver tests [162,163], to stimulate impaired biliary secretion, to improve histological appearance (over 2 years) [164] and nutritional status. The optimal dose of UDCA and its impact on survival in CF remain to be established.

Treatment of complications of cirrhosis is not different from other liver diseases. Medical treatment of



portal hypertension with beta blockers and/or endoscopic treatment of varices has not been adequately evaluated in CFALD whereas elective shunt surgery in portal hypertensive patients has allowed long-term survival in a case series [165]. Outcome of liver transplantation is comparable to that for other end-stage liver diseases.

### Recommendations

1. CFALD affects a third of patients with CF during long-term follow-up, but is not well defined. It may be disclosed by detection of hepatomegaly (III/C2), annual performance of serum liver tests (III/C2), and, if abnormal, ultrasound of the liver (III/C2).
2. UDCA (20–30 mg/kg/d) improves serum liver tests (I/C1) and histological parameters (III/C1) in CFALD. No medical therapy of proven long-term benefit exists in CFALD (III/C2). Liver transplantation is the treatment of choice in end-stage CFALD (III/B1).

## 8.2. Progressive familial intrahepatic cholestasis

### 8.2.1. Classification

Progressive familial intrahepatic cholestasis (PFIC) summarizes a group of three inherited cholestatic diseases which may start early after birth or at young age and may rapidly progress to end-stage disease [166]. Mutations in canalicular transporter genes of the ATP-binding cassette (ABC) transporters are responsible for these rare disorders.

*PFIC type 1* (formerly “Byler disease”) typically presents in the neonatal period with signs and symptoms (pruritus!) of liver disease. Elevation of serum transaminases, bilirubin and bile acids is contrasted by low levels of  $\gamma$ GT (in contrast to biliary atresia and Alagille syndrome). Liver histology reveals fibrosis, but no bile duct proliferation. Most patients develop end-stage liver disease before the end of the first decade of life. Diarrhea, pancreatitis, failure to thrive, and hearing deficits are extrahepatic manifestations of this genetic defect caused by mutations in the *ATP8B1* gene which encodes a phospholipid (phosphatidylserine?) flippase, FIC1 [167,168].

*PFIC type 2* (formerly “Byler syndrome”) presents like PFIC type 1 in early childhood with clinical and biochemical signs and symptoms of progressive liver disease, but low levels of  $\gamma$ GT. Histology reveals portal inflammation and giant cell hepatitis. Electron microscopic studies show coarse granular bile in PFIC1 and amorphous bile in PFIC2. PFIC2 is caused by mutations in the *ABCB11* gene which encodes the canalicular bile salt export pump, ABCB11/BSEP [169]. The course of PFIC2 is complicated by development of hepatocellular carcinoma at considerable rates [170] making liver transplantation an attractive treatment option.

*PFIC type 3* typically presents in the first years of childhood with progressive cholestasis [171], although disease manifestation and cirrhosis in adulthood has also been described most recently [95]. In contrast to PFIC1 and PFIC2,  $\gamma$ GT is usually markedly elevated in PFIC3 and histology reveals, in addition to portal inflammation and fibrosis/cirrhosis, massive bile duct proliferation. PFIC3 may be associated with intrahepatic gallstone disease. PFIC3 is caused by mutations in the *ABCB4* gene which encodes the canalicular phospholipid transporter, ABCB4/MDR3 [171].

### 8.2.2. Therapy

No medical therapy of proven benefit for the long-term prognosis of PFIC exists. Supplementation with medium chain triglycerides and fat-soluble vitamins is generally recommended in children. UDCA has been reported to improve biochemical tests in almost 50% of patients with PFIC3 [172], but generally does not affect PFIC1 and PFIC2. Rifampicin may alleviate pruritus. Partial biliary diversion and ileal exclusion have been reported in case series to improve signs and symptoms of particularly PFIC1 and also PFIC2 [173,174]. Liver transplantation is the recommended treatment of end-stage disease in PFIC.

### Recommendations

1. PFIC type 1, 2 and 3 are rare chronic progressive cholestatic disorders of early childhood and adolescence. PFIC type 1 and 2 are characterized by low  $\gamma$ GT, severe pruritus and various extrahepatic manifestations.
2. No medical therapy of proven benefit for the long-term prognosis of PFIC exists (III/C2). UDCA improves serum liver tests in a part of PFIC3 patients (III/C2). Rifampicin may alleviate pruritus (III/C2). Partial biliary diversion has shown beneficial clinical and biochemical effects in PFIC1 and PFIC2 (III/C2). Liver transplantation is recommended for end-stage disease (III/B1).

## 8.3. Benign recurrent intrahepatic cholestasis

Benign recurrent intrahepatic cholestasis (BRIC) type 1 and 2 are acute cholestatic disorders of adolescence and adulthood and represent the benign forms of PFIC1 and PFIC2 mainly caused by missense mutations in the *ATP8B1* and *ABCB11* genes [166,171]. BRIC is characterized by acute episodes of cholestasis, jaundice and severe pruritus caused by unknown factors which after weeks or months completely resolve to start again after an asymptomatic period of months to years. BRIC1 like PFIC1 may be accompanied by pancreatitis, whereas BRIC2 may be accompanied by gallstone dis-

ease [166]. Liver fibrosis has been described in cases of BRIC indicating a continuum between BRIC and PFIC in some cases [175].

No effective medical therapy of BRIC exists. UDCA and rifampicin have been anecdotally reported to affect the course of BRIC as has nasobiliary drainage [176].

### Recommendations

1. BRIC is characterized by acute episodes of cholestasis, jaundice and severe pruritus which after weeks to months completely resolve (III/C1).
2. No evidence-based treatment of BRIC is known. Treatment attempts with UDCA, rifampicin or nasobiliary drainage are still experimental (III/C2).

#### 8.4. Alagille syndrome

Alagille syndrome is an autosomal dominant multiorgan disease of children and adolescents which is characterized by chronic progressive cholestasis with ductopenia without relevant inflammatory changes in liver histology [177]. The extrahepatic signs and symptoms with involvement of nearly every organ system including heart, kidney, skeleton, central nervous system and a typical facies with hypertelorism, deep-set eyes and a flat nasal bridge may lead to the diagnosis of Alagille syndrome in young cholestatic patients suffering from often severe itch. The disease is caused by mutations in the *JAG1* gene in 70% of patients. No effective medical treatment exists. Anecdotally, partial biliary diversion has been reported to cause relief from severe pruritus.

### Recommendations

1. Alagille syndrome is characterized by cholestasis with pruritus and ductopenia at early age in combination with various extrahepatic stigmata and symptoms indicating multiorgan involvement as a consequence of *JAG1* mutations (III/C2).
2. No effective medical treatment is known (III/C2).

## 9. Drug-induced cholestatic liver disease

Acute drug-induced cholestatic injury represents one of three major forms of drug-induced liver injury (DILI) and has been defined by an international consensus panel by an isolated elevation of serum alkaline phosphatase (AP)  $>2 \times$  ULN or an alanine aminotransferase (ALT)/AP ratio (both elevated above ULN)  $<2$  [178]. In comparison, drug-induced hepatocellular injury as the predominant form of DILI is defined by isolated ALT  $>2 \times$  ULN or an ALT/AP ratio (both

elevated above ULN)  $>5$ , whereas mixed type injury is defined by an ALT/AP ratio of 2–5. Drug-induced cholestatic injury has a better prognosis than hepatocellular injury [179]. Several hundred drugs, herbal remedies, and illegal compounds have been reported to trigger drug-induced cholestatic injury. Adverse liver reactions are predictable and dose dependent only in a very few cases, whereas the vast majority is caused by unpredictable idiosyncratic or hypersensitive mechanisms. For many drugs, the reported prevalence of DILI is between 1 in 10,000 and 1 in 100,000 patients, and about 30% of cases with DILI are cholestatic. However, these estimates are weakened by considerable underreporting of DILI. Both environmental and genetic factors may determine susceptibility [180]. Genetically determined variations of hepatobiliary transporter and biotransformation enzyme expression and function may be important risk factors for an individual's susceptibility to cholestasis under conditions of xenobiotic stress by drugs.

### 9.1. Diagnosis

Because there are no specific diagnostic tests, diagnosis requires clinical suspicion, a careful drug history, consideration of the temporal relationship between drug intake and liver disease and exclusion of other disorders. Rechallenge could confirm the diagnosis, but is potentially harmful, unethical and not indicated in clinical practice; inadvertent re-challenge nevertheless may sometimes lead to diagnosis. When drug-induced cholestatic injury is assumed, liver biopsy is usually not required, and the natural course after stopping of drug administration is carefully followed until normalization of serum liver tests within 3 months in most cases. A severe, progressive or prolonged course may require liver biopsy to get additional information on the type of liver injury and to exclude other causes of liver cholestasis. Abdominal ultrasound is indicated to exclude other liver diseases (see Introduction 1).

### 9.2. Pathogenetic mechanisms and most frequent drugs

Drug-induced cholestasis may be based on two major mechanisms and sites of action, [1] inhibition of hepatocellular transporter expression and/or function with alteration of bile secretion at the hepatocellular level (Table 5) and [2] induction of an idiosyncratic inflammatory or hypersensitive reaction at the bile ductular/choangiocellular level with ductular/ductal cholestasis, which can also interfere with hepatocyte bile secretion (Table 5). Rarely, drugs induce a vanishing bile duct syndrome (VBDS) that can progress to biliary cirrhosis [181,182]. Various factors such as age, gender, dose, or co-administered medications may affect the risk to develop drug-induced hepatic injury [183].

**Table 5**  
**Most frequent drugs causing hepatocellular or ductular/ductal cholestasis.**

Hepatocellular cholestasis	Ductular/ductal cholestasis
Sex hormones	Allopurinol
Carbamazepine	Amoxicillin-clavulanic acid
Chlorpromazine	Azathioprine
Amoxicillin-clavulanic acid	Barbiturates
Trimethoprim-sulfamethoxazole	Captopril
Erythromycin, Clarithromycin	Carbamazepine
Nitrofurantoin	Chlorpropamide
Chlorpropamide	Clindamycin
Azathioprine	Phenytoin
Cyclosporine	Sulpiride
Propafenone	Trimethoprim-sulfamethoxazole
Nifedipine	Medicinal herbs
Medicinal herbs	
NSAIDs, nimesulide	

### 9.3. Treatment

There is no effective treatment for drug-induced cholestasis except for withdrawal of the drug [184]. Prevention and early detection of abnormal serum liver tests, together with prompt withdrawal of the suspected drug are crucial to avoid serious liver injury. In some cases, hepatotoxicity is severe, disabling or life-threatening and liver transplantation may be required. Some studies have reported that ursodeoxycholic acid (UDCA) may beneficially affect cholestasis in two-thirds of cases [185]. A potential benefit of corticosteroid therapy in cases of drug-induced cholestasis has been reported occasionally and may be particularly expected in hypersensitivity-induced cholestasis, but no relevant controlled trials are available on this subject [182]. The outcome of drug-induced cholestatic injury, after withdrawal of the drug, is generally good [186]. Occasionally it is followed by prolonged cholestasis. The prototype drug causing cholestasis longer than 6 months is chlorpromazine; it can cause the “vanishing bile duct syndrome in drug-induced liver disease”, leading to permanent liver damage [187]. A minority of the patients who had a drug-related liver injury shows, during follow-up, abnormal liver test and persistent liver damage at histology [186].

### Recommendations

1. Diagnosis of drug-induced cholestatic liver disease (AP >2× ULN or ALT (×ULN)/AP (×ULN) ratio <2) is mainly supported by a temporal relationship between drug intake and onset of clinical picture and exclusion of other causes (III/C1). A liver biopsy is not mandatory (III/C2).
2. Acute withdrawal of the suspected drug and careful clinical and biochemical monitoring are recom-

mended (III/C2). Therapeutic attempts with UDCA or corticosteroids are regarded as experimental due to lack of adequate controlled trials (III/C2).

## 10. Cholestatic disorders in pregnancy

### 10.1. Intrahepatic cholestasis of pregnancy (ICP)

Intrahepatic cholestasis of pregnancy (ICP, also known as obstetric cholestasis) is a reversible form of cholestasis characterized by (i) intense pruritus in pregnancy (starting in the second or third trimester of pregnancy in most patients), (ii) elevated serum ALT activities and fasting serum bile acid levels, and (iii) spontaneous relief of signs and symptoms after delivery (within 4–6 weeks) [188,189]. In Europe, about 0.4–2.0% of pregnancies are affected [188,190]. The clinical importance of ICP lies in the potential fetal risks (spontaneous or iatrogenic prematurity, asphyxial events during delivery, intrauterine death), albeit perinatal mortality rates from recent studies (9/1000) are comparable to whole population figures, most likely due to improvements in obstetric and neonatal care [191]. Pruritus (typically worse at night) impairs the mother’s quality of life. Only infrequently, ICP is associated with steatorrhea and postpartum haemorrhage due to vitamin K deficiency.

The pathogenesis of ICP is multifactorial, with genetic, hormonal and environmental factors playing important roles. During ICP, there is an increased flux of bile acids from the mother to the fetus, as indicated by elevated bile acid levels in amniotic fluid, cord blood and meconium [192]. The central role of hormonal factors is supported by the higher ICP incidence in twin pregnancies and the observation that high-dose oral contraceptives and progesterone can trigger ICP [188]. An increased ICP incidence in family members and ethnic differences point to genetic factors. Recent genetic studies have identified gene variants of hepatocanalicular transport proteins (ATP-binding cassette [ABC] transporter B4 = phosphatidylcholine floppase, ABC transporter B11 = bile salt export pump, ABC transporter C2 = conjugated organic anion transporter, ATP8B1 = FIC1) and their regulators (e.g., the bile acid sensor farnesoid X receptor, FXR) in some ICP patients [189]. Mild malfunction of these hepatocanalicular transporters could trigger cholestasis when their transport capacity for hormones or other substrates is exceeded during pregnancy. Currently, genetic tests are performed in research laboratories only and are not applicable for diagnosis or risk stratification. However, mutation analysis of *ABCB4* might be considered in the future if cholestasis (with increased  $\gamma$ GT levels) persists after delivery.

### 10.1.1. Diagnosis

The skin should be inspected to differentiate scratching lesions from other skin disorders such as eczema and pruritic eruption of pregnancy. Although pruritus can precede any abnormalities in liver function, serum liver tests (ALT, bilirubin,  $\gamma$ GT, bile acids, prothrombin time) are to be performed in every pregnant woman who experiences itching and to be repeated if normal in case of persistent pruritus. The diagnosis of cholestasis of pregnancy is based on otherwise unexplained pruritus and elevated serum bile acid concentrations ( $\geq 11 \mu\text{mol/L}$ ) [192]. Isolated elevation of bile acids may occur but this is uncommon; in the majority of patients, ALT activities are elevated as well. Bile acids are the most sensitive indicator for cholestasis of pregnancy and may precede the abnormalities of other serum liver tests. Bile acid levels  $>40 \mu\text{mol/L}$  any time during pregnancy and early onset of ICP ( $<33$  weeks of gestation) might be associated with significantly increased fetal complication rates [190,193–195]. ICP patients with *ABCB4* variants tend to display elevated  $\gamma$  GT levels, which are otherwise normal in ICP. Mild jaundice with serum levels of conjugated bilirubin only moderately elevated occurs in 10–15% of cases. Liver biopsy is generally not warranted.

Pre-eclampsia and acute fatty liver of pregnancy are pregnancy specific causes of abnormal serum liver tests that may form part of the differential diagnosis in atypical or early ICP cases (Table 6).

Persistent abnormalities after delivery should prompt reconsideration of other chronic liver diseases like PBC, PSC, *ABCB4* deficiency or chronic hepatitis C, which may be associated with development of pruritus during late pregnancy.

### 10.1.2. Therapy

Ursodeoxycholic acid (UDCA, 10–20 mg/kg per day) is regarded as the first-line treatment for ICP based on evidence obtained from randomized clinical trials [193,194,197–200]. UDCA may improve pruritus and serum liver tests in 67–80% of ICP patients, but reduction of fetal complication rates is uncertain as fetal complication rates were low in recent trials both in UDCA and placebo-treated patients.

Dexamethasone (12 mg/day for 7 days) promotes fetal lung maturity, but is ineffective in reducing pruritus and ALT levels in patients with ICP [197]. Thus, this drug is not an adequate treatment of ICP [191].

*S*-Adenosyl-L-methionine is less effective than UDCA [200], but may have an additive effect [199]. If pruritus does not adequately respond to UDCA standard therapy for several days, the dose may be increased up to 25 mg/kg/day [201], or alternatively, treatment with *S*-adenosyl-methionine (combined with UDCA) or rifampicin might be considered on an individual basis (see Section 4.1). Topical emollients are safe but their efficacy is unknown.

Active obstetric management (including amniocentesis and generous induction of labour) has been reported to reduce perinatal mortality but increases intervention and complication rates [194,202,203]. The practice of considering delivery at (36 to) 38 weeks of gestation appears to prevent stillbirth beyond that gestation, but is not evidence-based [191].

## 10.2. Diagnosis and treatment of obstructive cholestasis during pregnancy

Although up to 10% of patients develop stones or sludge over the course of one pregnancy, symptomatic

**Table 6**  
Characteristics of ICP, HELLP Syndrome and acute fatty liver of pregnancy [196].

	ICP	HELLP	AFLP
% Pregnancies	0.1–1.0	0.2–0.6	0.005–0.01
Trimester	(2 or) 3	3 or postpartum	3 or postpartum
Family history	Often	No	Occasionally
Presence of preeclampsia	No	Yes	50%
Typical clinical features	Pruritus Elevated serum ALT/ AST fasting bile acids	Haemolysis Elevated serum liver tests Thrombocytopenia (often $<50,000/\mu\text{L}$ )	Liver failure with mild jaundice, coagulopathy, encephalopathy, hypoglycemia, DIC
ALT (above normal)	Mild to 10–20-fold	Mild to 10–20-fold	5–15-fold, variable
Bilirubin	$<5 \text{ mg/dL}$ ( $<85 \mu\text{mol/l}$ )	Mostly $<5 \text{ mg/dL}$ ( $<85 \mu\text{mol/l}$ )	Often $<5 \text{ mg/dL}$ ( $<85 \mu\text{mol/l}$ )
Hepatic imaging	Normal	Hepatic infarcts, hematomas, hepatic rupture	Fatty infiltration
Maternal mortality (%)	0	1–25	7–18
Fetal/perinatal mortality (%)	0.4–1.4	11	9–23
Recurrence in subsequent pregnancies (%)	45–70	4–19	20–70 (carriers of LCHAD mutations) Rare (others)

LCHAD:  $\alpha$ -subunit, long-chain 3-hydroxyacyl-CoA dehydrogenase.

gallstones occur in only 1.2% of these pregnancies [204]. The diagnosis is based on clinical symptoms, elevated serum liver tests (ALT, bilirubin,  $\gamma$ GT, AP) and abdominal (or endoscopic) ultrasound. Obstructive cholestasis due to an impacted common bile duct stone or worsening gallstone pancreatitis are indications to proceed to endoscopic retrograde cholangiography (ERCP), sphincterotomy and stone extraction under antibiotic coverage. Several series have demonstrated the safety of ERCP in pregnancy [205,206]. An experienced physician should perform the intervention. Ultrasound-guidance might be helpful to minimize ionising radiation of the fetus (uterus dose 24 mSv/min). For deep sedation, consultation of an anesthesiologist and obstetrician is recommended. Meperidine, propofol, fentanyl and midazolam may be used at low doses [207]. Ampicillin is the preferred antibiotic and is compatible with breastfeeding [207] (Table 7).

### 10.3. Drugs for cholestatic conditions during pregnancy

Women with cholestatic liver diseases may be of childbearing age, and an uncomplicated pregnancy with no disease flare is expected in those with mild or inactive disease. The course of autoimmune hepatitis or overlap syndrome in pregnancy is highly variable, and a flare of activity may occur during pregnancy or, more likely, in the post partum period. Table 7 summarizes the safety of drugs for cholestatic liver diseases [208].

**UDCA.** Although UDCA is not approved, but likely to be compatible, for use during early pregnancy, UDCA can be administered in cholestatic liver disease, when the pregnant woman is symptomatic during the second or third trimesters [209]. No adverse effects in mothers or newborns have been observed [210] including recent RCT, using UDCA for up to 8 weeks [189,197–199]. UDCA is not approved during breastfeeding, but likely to be safe for the baby, since significant amounts of UDCA cannot be found in milk during lactation.

**Corticosteroids.** The use of prednisolone is considered safe during pregnancy and lactation, but is associated with an increased risk of cleft palate in children to women using the drug in the first trimester [211]. An increased risk of premature rupture of membranes and adrenal insufficiency was reported in the transplant setting [212].

**Azathioprine.** Azathioprine appears to be a safe drug during pregnancy, although it is teratogenic in animals. Steadily increasing experience is being reported in women with autoimmune hepatitis, rheumatoid arthritis, inflammatory bowel diseases, and after organ transplantation [208,213]. The benefits and risks of therapy should be discussed in detail with the patient. Although very little azathioprine is excreted in breast milk, breastfeeding should be discussed on an individual basis.

**Table 7**  
Medical treatment options in cholestatic disorders during pregnancy [207,208].

Indication/drug	Fetal risk (FDA category)	Use and safety
<b>Immune-mediated disorders</b>		
UDCA	B	Low risk
Prednisolone	C	Low risk: increased risk of cleft palate [211], adrenal insufficiency [212]
Azathioprine	D	Low risk
<b>Bacterial cholangitis</b>		
Ampicillin	B	Low risk
<b>Sedation and analgesia</b>		
Fentanyl	C	Use in low doses
Meperidine	B	Use in low doses
Midazolam	D	Use in low doses
Propofol	B	Avoid in first (and second) trimester

Fetal risk categories (FDA): A – no risk; B – risk in animal studies, but not in humans; C – human risk cannot be excluded; D – risk; X – absolute contraindication.

### Recommendations

1. Diagnosis of ICP is based on (i) pruritus in pregnancy, (ii) elevated serum ALT activities and fasting bile acid levels, and (iii) exclusion of other causes of liver dysfunction or itching (II-2/C2). ICP is confirmed when serum liver tests completely normalize after delivery.
2. Women with ICP should be advised that the incidence of premature birth is increased, both spontaneous and iatrogenic (II-2/B1). No specific fetal monitoring can be recommended (III/C2). UDCA ameliorates pruritus and improves serum liver tests (I/B1), but there are insufficient data concerning protection against fetal complications (II-1/C2). Vitamin K should be supplemented when prothrombin time is prolonged (III/C2). Timing of delivery should be discussed on an individual basis (II-2/C2).
3. UDCA can be administered to pregnant women with cholestatic liver diseases during the second or third trimesters, when the patients are symptomatic (I/B1). Prednisolone  $\pm$  azathioprine for treatment of autoimmune hepatitis should be continued during pregnancy to prevent disease flares, which might be more deleterious to pregnancy outcome than any potential risk of the medication (III/C2).
4. Symptomatic bile duct stones in pregnancy are treated by endoscopic sphincterotomy and stone extraction (II-3/B1). X-ray is not absolutely contraindicated even in the first trimester (III/C2). Patients with simultaneous gallbladder and bile duct stones who are asymptomatic after clearance of the bile duct should undergo cholecystectomy post partum (III/C2).

## 11. Management of extrahepatic manifestations

### 11.1. Pruritus

Pruritus can be a feature of any cholestatic disease and can be of sufficient severity, in some instances, also disabling. The precise mechanism of cholestatic pruritus remains unclear [214]. Fluctuation is characteristic (both within the day and over longer periods of time), and pruritus can lessen as end-stage liver disease develops. In the absence of obstructive bile duct lesions amenable to endoscopic, radiological or surgical correction treatment (Fig. 2) focuses entirely on systemic medication (no topical agents have demonstrated efficacy). There is no evidence to suggest that UDCA lessens cholestatic itch (indeed paradoxical worsening of itch has been reported anecdotally following introduction of this agent) except in the context of intrahepatic cholestasis of pregnancy. Cholestyramine is widely used as first-line treatment although the evidence basis to support this is limited, largely because the agent entered widespread use before the era of evidence-based medicine [215]. Poor tolerance due to the taste of this agent can be a problem (which can sometimes be addressed by flavoring with fruit juice). When both agents are used UDCA and cholestyramine should be spaced a minimum of four hours apart to prevent binding and loss of efficacy [216].

The pregnane X receptor (PXR) agonist, rifampicin, is widely used as second-line treatment and has a strong evidence base [217,218]. Ongoing efficacy is reported over up to 2 years of treatment (mirroring clinical experience) [219]. Urine, tears and other body secretions are discoloured during treatment and, in case series, drug-induced hepatitis and significant liver dysfunction after two to three months have been reported in up to 12% of cholestatic patients [220]. In light of this, low dose initiation with monitoring before dose escalation is recommended.

Oral opiate antagonists can be used as third-line agents [218]. However problems have been reported with an opiate withdrawal-like reaction on initiation (which can be ameliorated, to some extent by use of an i.v. naloxone induction phase in which the dose is rapidly escalated to a level at which conversion to the lowest dose oral opiate antagonist preparation can be instituted [221,222] and ongoing problems resulting from pain and confusion.

There is evidence to support the use of sertraline, although the mechanism of its action remains unclear [223]. Clinical experience of both opiate-antagonists and sertraline used for pruritus treatment has been disappointing for many clinicians and the importance of fully exploring the use of cholestyramine and rifampicin therapy before resorting to these agents is emphasized. There are anecdotal observations to support the use of

gabapentin and cimetidine in cases of resistance pruritus. The use of antihistamines, ondansetron and phenobarbitone is not recommended for reasons of lack of efficacy, limited efficacy and excessive side-effect profile, respectively.

There is case report evidence to advocate the use of invasive physical approaches in resistant pruritus cases. These approaches include extracorporeal albumin dialysis [224], plasmapheresis [225,226] and bile duct drainage [176,227]. The invasive nature of these approaches makes them only suitable in patients who are resistant to medical therapies. Transplantation is effective for the control of cholestatic itch but raises issues of organ allocation priority and patient risk in patients who would not otherwise require transplantation [228]. Itch quantification using a visual analogue scale can help in the assessment of response to interventions. Objectification of itch through physical measurement of scratching activity has been advocated as a more accurate measure. It is, in practice, limited to use as a research tool. Treatment of pruritus in cholestatic liver disease has been subjected to systematic review [217,218].

#### Recommendations (Fig. 2)

1. Cholestyramine 4 g up to four times daily or other resins are regarded as first-line treatment of pruritus (II-2/B1). Resins should be spaced away from UDCA and other drugs by at least 4 hours (II-3/B1).
2. Rifampicin is regarded as second-line treatment introduced at 150 mg with monitoring of serum liver tests which may be increased to a maximum of 600 mg daily (I/A1).
3. Naltrexone, an oral opiate antagonist, at a dose of 50 mg daily should be considered as third-line treatment starting at a low dose of 25 mg (I/B1). It should only be considered following proven lack of efficacy, intolerance or side-effects with cholestyramine or other resins and rifampicin (III/C1).
4. Sertraline may be considered for patients resistant to above mentioned treatments as fourth-line treatment (II-2/C2).
5. Patients resistant to the above agents can be treated with drugs with anecdotal support, or referred to specialized centers, where more invasive approaches should be considered (III/C2).
6. Liver transplantation is effective, but should only be considered when all available interventions above have proven ineffective (III/C1).

### 11.2. Fatigue

PBC can be characterized by fatigue, the degree of which is unrelated to the severity of the underlying

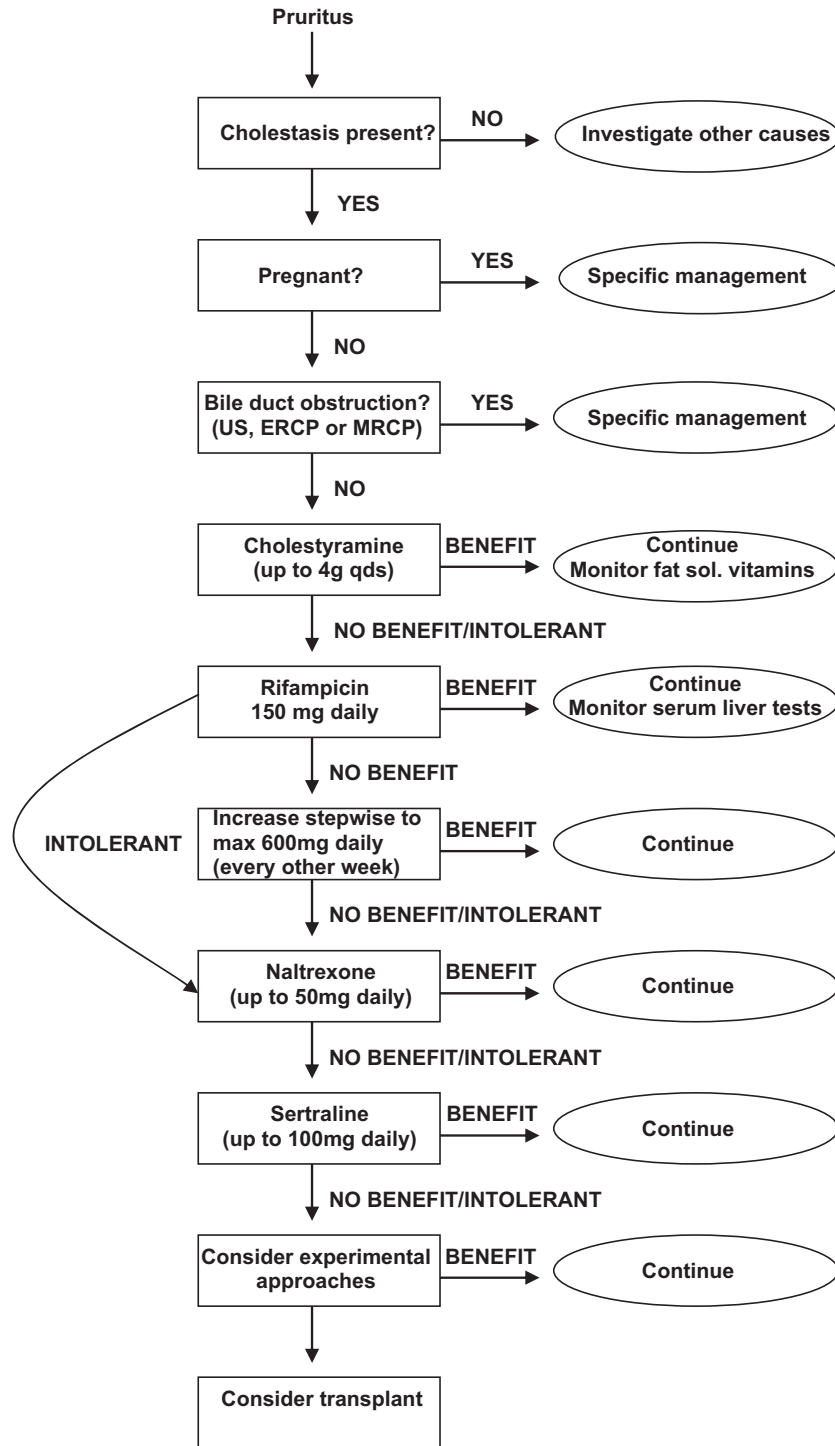


Fig. 2. Management of pruritus in cholestasis. Abbreviations: US, ultrasound; MRCP, magnetic resonance cholangiopancreatography; ERCP, endoscopic retrograde cholangiopancreatography.

liver disease. The issue of the extent to which other cholestatic liver diseases can be associated with fatigue is poorly studied. Before ascribing fatigue to PBC it is essential to exclude other associated or non-associated causes of fatigue which may be amenable to specific intervention. This includes the presence of AIH-like features which may be amenable to immunosuppressive

therapy. Fatigue in PBC shows only a limited association with depression [229], but stronger associations with autonomic dysfunction (in particular orthostatic hypotension [230]) and sleep disturbance (in particular excessive daytime somnolence [230]) and which may themselves be amenable to specific intervention (there is, in particular, case series evidence to support the

use of modafinil in patients with fatigue associated with prominent daytime somnolence [231–233]). There are no specific interventions able to reverse fatigue in PBC, although supportive and understanding clinical care will improve patients' capacity to cope [234]. Fatigue may not improve significantly following liver transplantation which is therefore not appropriate in patients lacking other indications.

### Recommendations

1. Associated disease (e.g., hypothyroidism, anemia, diabetes, depression etc.) or medication use characterized by fatigue should be actively excluded (III/C2).
2. Supportive measures including minimization of factors likely to exacerbate autonomic dysfunction (e.g., excessive anti-hypertensive medication) and sleep disturbance (e.g., caffeine in the evenings) should be considered (III/C2). Psychological support should be considered to assist with development of coping strategies (II-2 & II-3/C2).
3. Liver transplantation is not appropriate for treatment of fatigue in the absence of other indications (III/C1).

### 11.3. Osteoporosis

The degree to which patients with cholestatic liver disease are at increased risk of osteoporosis is unclear, with contradictory reports in the literature. This largely reflects the case mix in different centres (with significant age, disease severity and degree of cholestasis differences). A consensus view would be that patients with end-stage liver disease and/or a high degree of cholestasis are at increased risk of developing osteoporosis, with a significantly smaller risk in other groups. In these latter groups established population risk factors for osteoporosis (smoking, inactivity, family history, low body weight, age and female gender) outweigh any cholestasis-related risk. Compared to healthy controls, male patients with cholestatic liver disease have a higher disease-related osteoporosis risk increase (although lower absolute risk) than female patients. The use of calcium and vitamin D supplements is supported by epidemiological data (reduction or reversal of the natural rate of bone loss) but there are no trial data to support or refute this treatment approach [235]. Hormone replacement therapy is effective in post-menopausal female patients [236,237]. Testosterone therapy should be avoided in male patients because of risk of hepatocellular carcinoma. There are trial data to support the use of bisphosphonates (particularly alendronate) where osteoporosis is present [238,239]. There are limited data to support the use of raloxifene and sodium fluoride [240,241]. Bone mineral density assessment (DEXA) is a useful guide to treatment and should be undertaken where possible in all patients at presentation, with fol-

low-up assessment at between 1 and 5 years depending on outcome and general osteoporosis risk [242].

### Recommendations

1. The risk for osteoporosis should be clinically assessed for all cholestatic patients with emphasis on reversible risk factors and lifestyle advice (III/C2).
2. Bone mineral density should be assessed by DEXA in chronic cholestatic liver disease at presentation (III/C2). Rescreening should be performed up to annually depending on degree of cholestasis or other individual risk factors (III/C2).
3. Supplementation with calcium (1000–1200 mg/day) and vitamin D (400–800 IU/day) in all patients with cholestatic liver disease should be considered but is not evidence-based (III/C2).
4. Alendronate or other bisphosphonates are indicated at a *T* score <−2,5 (DEXA) or following pathological fracture (I/B1) and may be appropriate at a *T* score <−1,5 (III/C2).

### 11.4. Fat-soluble vitamin substitution

Fat malabsorption can complicate highly cholestatic disease variants, although the risk is lower in less cholestatic patients than has previously been considered to be the case (with the exception of children where degrees of fat malabsorption are typically higher). Parenteral vitamin K supplementation should be given prophylactically in overt cholestasis prior to any invasive procedure and in the context of bleeding. Assessment of blood levels of fat-soluble vitamins has been advocated to guide the need for supplementation but this approach is not widely used and is not recommended.

### Recommendations

1. Calcium and vitamin D enteral supplementation should be considered in all cholestatic patients as part of the osteoporosis prevention protocol (III/C2).
2. Vitamin A, E and K should be supplemented enterally in adults in the context of overt cholestasis, where the clinical features of steatorrhea are present or where fat-soluble vitamin levels are proven to be low (III/C2).
3. Parenteral vitamin K should be given prophylactically prior to invasive procedures in overt cholestasis and in the context of bleeding (II-2/C1).

### 11.5. Varices and hepatocellular carcinoma

Varices and hepatocellular carcinoma (HCC) development occur in advanced cholestatic liver disease as in other forms of chronic liver disease and are associated



with impaired prognosis [243,244]. Screening, prophylaxis and treatment approaches should be adopted as in other chronic liver disease settings [245,246]. However, a platelet count of  $<200,000/\text{mm}^3$ , serum albumin  $<40\text{ g/L}$  and serum bilirubin  $>20\text{ }\mu\text{mol/L}$  were independent risk factors for the presence of oesophageal varices in one cohort of cholestatic patients with PBC ( $>90\%$ ) and PSC [247]. The proposed threshold of endoscopic screening for oesophageal varices may be valid for PBC rather than cholestatic liver disease in general.

### Conflicts of interest disclosure

- Ulrich Beuers has received lecture fees from the Falk Foundation, Gilead, Roche, Schering-Plough and Zambon.
- Kirsten M. Boberg has received research funding from Meda A/S.
- Roger W. Chapman has received research support and lecture fees from the Falk Foundation.
- Olivier Chazouillères has nothing to disclose.
- Pietro Invernizzi has acted as an advisor and lecturer for Instrumentation Laboratory, Inova Diagnostics, Menarini Diagnostics and Euroimmun.
- David E.J. Jones has nothing to disclose.
- Frank Lammert has nothing to disclose.
- Albert Parès has received research support from Gambro Dialysatoren GmbH, Hechingen, Germany.
- Michael Trauner has received research support and lecture fees from the Falk Foundation.
- Antonio Benedetti has nothing to disclose.
- Peter L.M. Jansen is acting as an advisor to Biolex and Debiopharm and has received funds from Special Products.
- Hanns-Ulrich Marschall has received research support from the Falk Foundation and MEDA AB.
- James Neuberger has received speaker support from the Falk Foundation, Roche and Astellas and has been a principal investigator for Roche.
- Gustav Paumgartner has received speaker support from the Falk Foundation.
- Raoul Poupon has received lecture fees from the Falk Foundation, Sanofi-Aventis, Schering-Plough, Roche and Axcan.
- Jesús Prieto has received lecture fees from the Falk Foundation.

### References

- [1] Guyatt GH, Oxman AD, Vist GE, Kunz R, Falck-Ytter Y, Alonso-Coello P, et al. GRADE: an emerging consensus on rating quality of evidence and strength of recommendations. *BMJ* 2008;336:924–926.
- [2] Chazouillères O, Housset C. Intrahepatic cholestasis. In: Rodés J, editor. *Textbook of hepatology: from basic science to clinical practice*. Oxford: Blackwell; 2007. p. 1481–1500.
- [3] Heathcote EJ. Diagnosis and management of cholestatic liver disease. *Clin Gastroenterol Hepatol* 2007;5:776–782.
- [4] Freeman ML, Nelson DB, Sherman S, Haber GB, Herman ME, Dorsher PJ, et al. Complications of endoscopic biliary sphincterotomy. *N Engl J Med* 1996;335:909–918.
- [5] Ludwig J. Idiopathic adulthood ductopenia: an update. *Mayo Clin Proc* 1998;73:285–291.
- [6] Heathcote EJ. Management of primary biliary cirrhosis. The American Association for the Study of Liver Diseases practice guidelines. *Hepatology* 2000;31:1005–1013.
- [7] Metcalf JV, Mitchison HC, Palmer JM, Jones DE, Bassendine MF, James OF. Natural history of early primary biliary cirrhosis. *Lancet* 1996;348:1399–1402.
- [8] Invernizzi P, Lleo A, Podda M. Interpreting serological tests in diagnosing autoimmune liver diseases. *Semin Liver Dis* 2007;27:161–172.
- [9] Vergani D, Alvarez F, Bianchi FB, Cancado EL, Mackay IR, Manns MP, et al. Liver autoimmune serology: a consensus statement from the committee for autoimmune serology of the International Autoimmune Hepatitis Group. *J Hepatol* 2004;41:677–683.
- [10] Ludwig J, Dickson ER, McDonald GS. Staging of chronic nonsuppurative destructive cholangitis (syndrome of primary biliary cirrhosis). *Virchows Arch A Pathol Anat Histol* 1978;379:103–112.
- [11] Scheuer PJ. Primary biliary cirrhosis: diagnosis, pathology and pathogenesis. *Postgrad Med J* 1983;59:106–115.
- [12] Beuers U. Drug insight: mechanisms and sites of action of ursodeoxycholic acid in cholestasis. *Nat Clin Pract Gastroenterol Hepatol* 2006;3:318–328.
- [13] Poupon RE, Balkau B, Eschwege E, Poupon R. A multicenter, controlled trial of ursodiol for the treatment of primary biliary cirrhosis. UDCA-PBC Study Group. *N Engl J Med* 1991;324:1548–1554.
- [14] Heathcote EJ, Cauch-Dudek K, Walker V, Bailey RJ, Blendis LM, Ghent CN, et al. The Canadian Multicenter Double-blind Randomized Controlled Trial of ursodeoxycholic acid in primary biliary cirrhosis. *Hepatology* 1994;19:1149–1156.
- [15] Lindor KD, Dickson ER, Baldus WP, Jorgensen RA, Ludwig J, Murtaugh PA, et al. Ursodeoxycholic acid in the treatment of primary biliary cirrhosis. *Gastroenterology* 1994;106:1284–1290.
- [16] Combes B, Carithers Jr RL, Maddrey WC, Lin D, McDonald MF, Wheeler DE, et al. A randomized, double-blind, placebo-controlled trial of ursodeoxycholic acid in primary biliary cirrhosis. *Hepatology* 1995;22:759–766.
- [17] Pares A, Caballeria L, Rodes J, Bruguera M, Rodrigo L, Garcia-Plaza A, et al. Long-term effects of ursodeoxycholic acid in primary biliary cirrhosis: results of a double-blind controlled multicentric trial. UDCA-Cooperative Group from the Spanish Association for the Study of the Liver. *J Hepatol* 2000;32:561–566.
- [18] Corpechot C, Carrat F, Bonnard AM, Poupon RE, Poupon R. The effect of ursodeoxycholic acid therapy on liver fibrosis progression in primary biliary cirrhosis. *Hepatology* 2000;32:1196–1199.
- [19] Poupon RE, Lindor KD, Cauch-Dudek K, Dickson ER, Poupon R, Heathcote EJ. Combined analysis of randomized controlled trials of ursodeoxycholic acid in primary biliary cirrhosis. *Gastroenterology* 1997;113:884–890.
- [20] Goulis J, Leandro G, Burroughs A. Randomised controlled trials of ursodeoxycholic-acid therapy for primary biliary cirrhosis: a meta-analysis. *Lancet* 1999;354:1053–1060.
- [21] Gong Y, Huang Z, Christensen E, Gluud C. Ursodeoxycholic acid for patients with primary biliary cirrhosis: an updated systematic review and meta-analysis of randomized clinical trials using Bayesian approach as sensitivity analyses. *Am J Gastroenterol* 2007;102:1799–1807.

- [22] Shi J, Wu C, Lin Y, Chen YX, Zhu L, Xie WF. Long-term effects of mid-dose ursodeoxycholic acid in primary biliary cirrhosis: a meta-analysis of randomized controlled trials. *Am J Gastroenterol* 2006;101:1529–1538.
- [23] Lindor KD, Poupon R, Heathcote EJ, Thorneau T. Ursodeoxycholic acid for primary biliary cirrhosis. *Lancet* 2000;355:657–658.
- [24] Angulo P, Dickson ER, Thorneau TM, Jorgensen RA, Smith C, DeSotel CK, et al. Comparison of three doses of ursodeoxycholic acid in the treatment of primary biliary cirrhosis: a randomized trial. *J Hepatol* 1999;30:830–835.
- [25] Corpechot C, Carrat F, Bahr A, Chretien Y, Poupon RE, Poupon R. The effect of ursodeoxycholic acid therapy on the natural course of primary biliary cirrhosis. *Gastroenterology* 2005;128:297–303.
- [26] ter Borg PC, Schalm SW, Hansen BE, van Buuren HR. Prognosis of ursodeoxycholic acid-treated patients with primary biliary cirrhosis. Results of a 10-yr cohort study involving 297 patients. *Am J Gastroenterol* 2006;101:2044–2050.
- [27] Pares A, Caballeria L, Rodes J. Excellent long-term survival in patients with primary biliary cirrhosis and biochemical response to ursodeoxycholic acid. *Gastroenterology* 2006;130:715–720.
- [28] Corpechot C, Abenavoli L, Rabahi N, Chretien Y, Andreani T, Johanet C, et al. Biochemical response to ursodeoxycholic acid and long-term prognosis in primary biliary cirrhosis. *Hepatology* 2008;48:871–877.
- [29] Mitchison HC, Bassendine MF, Malcolm AJ, Watson AJ, Record CO, James OF. A pilot, double-blind, controlled 1-year trial of prednisolone treatment in primary biliary cirrhosis: hepatic improvement but greater bone loss. *Hepatology* 1989;10:420–429.
- [30] Leuschner M, Guldutuna S, You T, Hubner K, Bhatti S, Leuschner U. Ursodeoxycholic acid and prednisolone versus ursodeoxycholic acid and placebo in the treatment of early stages of primary biliary cirrhosis. *J Hepatol* 1996;25:49–57.
- [31] Leuschner M, Maier KP, Schlichting J, Strahl S, Herrmann G, Dahm HH, et al. Oral budesonide and ursodeoxycholic acid for treatment of primary biliary cirrhosis: results of a prospective double-blind trial. *Gastroenterology* 1999;117:918–925.
- [32] Rautiainen H, Karkkainen P, Karvonen AL, Nurmi H, Pikkarainen P, Nuutinen H, et al. Budesonide combined with UDCA to improve liver histology in primary biliary cirrhosis: a three-year randomized trial. *Hepatology* 2005;41:747–752.
- [33] Angulo P, Jorgensen RA, Keach JC, Dickson ER, Smith C, Lindor KD. Oral budesonide in the treatment of patients with primary biliary cirrhosis with a suboptimal response to ursodeoxycholic acid. *Hepatology* 2000;31:318–323.
- [34] Hempfling W, Grunhage F, Dilger K, Reichel C, Beuers U, Sauerbruch T. Pharmacokinetics and pharmacodynamic action of budesonide in early- and late-stage primary biliary cirrhosis. *Hepatology* 2003;38:196–202.
- [35] Christensen E, Neuberger J, Crowe J, Altman DG, Popper H, Portmann B, et al. Beneficial effect of azathioprine and prediction of prognosis in primary biliary cirrhosis. Final results of an international trial. *Gastroenterology* 1985;89:1084–1091.
- [36] Lombard M, Portmann B, Neuberger J, Williams R, Tygstrup N, Ranek L, et al. Cyclosporin A treatment in primary biliary cirrhosis: results of a long-term placebo controlled trial. *Gastroenterology* 1993;104:519–526.
- [37] Hendrickse MT, Rigney E, Gjaffer MH, Soomro I, Triger DR, Underwood JC, et al. Low-dose methotrexate is ineffective in primary biliary cirrhosis: long-term results of a placebo-controlled trial. *Gastroenterology* 1999;117:400–407.
- [38] Gonzalez-Koch A, Brahm J, Antezana C, Smok G, Cumsille MA. The combination of ursodeoxycholic acid and methotrexate for primary biliary cirrhosis is not better than ursodeoxycholic acid alone. *J Hepatol* 1997;27:143–149.
- [39] Combes B, Emerson SS, Flye NL, Munoz SJ, Luketic VA, Mayo MJ, et al. Methotrexate (MTX) plus ursodeoxycholic acid (UDCA) in the treatment of primary biliary cirrhosis. *Hepatology* 2005;42:1184–1193.
- [40] Hoofnagle JH, Davis GL, Schafer DF, Peters M, Avigan MI, Pappas SC, et al. Randomized trial of chlorambucil for primary biliary cirrhosis. *Gastroenterology* 1986;91:1327–1334.
- [41] Talwalkar JA, Angulo P, Keach JC, Petz JL, Jorgensen RA, Lindor KD. Mycophenolate mofetil for the treatment of primary biliary cirrhosis in patients with an incomplete response to ursodeoxycholic acid. *J Clin Gastroenterol* 2005;39:168–171.
- [42] Vuoristo M, Farkkila M, Karvonen AL, Leino R, Lehtola J, Makinen J, et al. A placebo-controlled trial of primary biliary cirrhosis treatment with colchicine and ursodeoxycholic acid. *Gastroenterology* 1995;108:1470–1478.
- [43] Poupon RE, Huet PM, Poupon R, Bonnand AM, Nhieu JT, Zafrani ES. A randomized trial comparing colchicine and ursodeoxycholic acid combination to ursodeoxycholic acid in primary biliary cirrhosis. UDCA–PBC Study Group. *Hepatology* 1996;24:1098–1103.
- [44] Neuberger J, Christensen E, Portmann B, Caballeria J, Rodes J, Ranek L, et al. Double blind controlled trial of D-penicillamine in patients with primary biliary cirrhosis. *Gut* 1985;26:114–119.
- [45] Gong Y, Klingenberg SL, Glud C. Systematic review and meta-analysis: D-penicillamine vs. placebo/no intervention in patients with primary biliary cirrhosis—Cochrane Hepato-Biliary Group. *Aliment Pharmacol Ther* 2006;24:1535–1544.
- [46] The results of a randomized double blind controlled trial evaluating malotilate in primary biliary cirrhosis. A European multicentre study group. *J Hepatol* 1993;17:227–35.
- [47] McCormick PA, Scott F, Epstein O, Burroughs AK, Scheuer PJ, McIntyre N. Thalidomide as therapy for primary biliary cirrhosis: a double-blind placebo controlled pilot study. *J Hepatol* 1994;21:496–499.
- [48] Angulo P, Patel T, Jorgensen RA, Thorneau TM, Lindor KD. Silymarin in the treatment of patients with primary biliary cirrhosis with a suboptimal response to ursodeoxycholic acid. *Hepatology* 2000;32:897–900.
- [49] Stojakovic T, Putz-Bankuti C, Fauler G, Scharnagl H, Wagner M, Stadlbauer V, et al. Atorvastatin in patients with primary biliary cirrhosis and incomplete biochemical response to ursodeoxycholic acid. *Hepatology* 2007;46:776–784.
- [50] Leuschner M, Holtmeier J, Ackermann H, Leuschner U. The influence of sulindac on patients with primary biliary cirrhosis that responds incompletely to ursodeoxycholic acid: a pilot study. *Eur J Gastroenterol Hepatol* 2002;14:1369–1376.
- [51] Iwasaki S, Ohira H, Nishiguchi S, Zeniya M, Kaneko S, Onji M, et al. The efficacy of ursodeoxycholic acid and bezafibrate combination therapy for primary biliary cirrhosis: a prospective, multicenter study. *Hepatol Res* 2008;38:557–564.
- [52] Invernizzi P, Alvaro D, Crosignani A, Gaudio E, Podda M. Tamoxifen in treatment of primary biliary cirrhosis. *Hepatology* 2004;39:1175–1176.
- [53] Mason AL, Farr GH, Xu L, Hubscher SG, Neuberger JM. Pilot studies of single and combination antiretroviral therapy in patients with primary biliary cirrhosis. *Am J Gastroenterol* 2004;99:2348–2355.
- [54] MacQuillan GC, Neuberger J. Liver transplantation for primary biliary cirrhosis. *Clin Liver Dis* 2003;7:941–956.
- [55] Milkiewicz P. Liver transplantation in primary biliary cirrhosis. *Clin Liver Dis* 2008;12:461–472.
- [56] Gautam M, Cheruvattath R, Balan V. Recurrence of autoimmune liver disease after liver transplantation: a systematic review. *Liver Transpl* 2006;12:1813–1824.

- [57] Chazouilleres O, Wendum D, Serfaty L, Montebault S, Rosmorduc O, Poupon R. Primary biliary cirrhosis–autoimmune hepatitis overlap syndrome: clinical features and response to therapy. *Hepatology* 1998;28:296–301.
- [58] Lohse AW, zum Buschenfelde KH, Franz B, Kanzler S, Gerken G, Dienes HP. Characterization of the overlap syndrome of primary biliary cirrhosis (PBC) and autoimmune hepatitis: evidence for it being a hepatic form of PBC in genetically susceptible individuals. *Hepatology* 1999;29:1078–1084.
- [59] Woodward J, Neuberger J. Autoimmune overlap syndromes. *Hepatology* 2001;33:994–1002.
- [60] Beuers U, Rust C. Overlap syndromes. *Semin Liver Dis* 2005;25:311–320.
- [61] Heathcote EJ. Overlap of autoimmune hepatitis and primary biliary cirrhosis: an evaluation of a modified scoring system. *Am J Gastroenterol* 2002;97:1090–1092.
- [62] Alvarez F, Berg PA, Bianchi FB, Bianchi L, Burroughs AK, Cancado EL, et al. International Autoimmune Hepatitis Group Report: review of criteria for diagnosis of autoimmune hepatitis. *J Hepatol* 1999;31:929–938.
- [63] Talwalkar JA, Keach JC, Angulo P, Lindor KD. Overlap of autoimmune hepatitis and primary biliary cirrhosis: an evaluation of a modified scoring system. *Am J Gastroenterol* 2002;97:1191–1197.
- [64] Chazouilleres O, Wendum D, Serfaty L, Rosmorduc O, Poupon R. Long term outcome and response to therapy of primary biliary cirrhosis–autoimmune hepatitis overlap syndrome. *J Hepatol* 2006;44:400–406.
- [65] Hennes EM, Zeniya M, Czaja AJ, Pares A, Dalekos GN, Krawitt EL, et al. Simplified criteria for the diagnosis of autoimmune hepatitis. *Hepatology* 2008;48:169–176.
- [66] Yamamoto K, Terada R, Okamoto R, Hiasa Y, Abe M, Onji M, et al. A scoring system for primary biliary cirrhosis and its application for variant forms of autoimmune liver disease. *J Gastroenterol* 2003;38:52–59.
- [67] Poupon R, Chazouilleres O, Corpechot C, Chretien Y. Development of autoimmune hepatitis in patients with typical primary biliary cirrhosis. *Hepatology* 2006;44:85–90.
- [68] Czaja AJ. The variant forms of autoimmune hepatitis. *Ann Intern Med* 1996;125:588–598.
- [69] Rust C, Beuers U. Overlap syndromes among autoimmune liver diseases. *World J Gastroenterol* 2008;14:3368–3373.
- [70] Silveira MG, Talwalkar JA, Angulo P, Lindor KD. Overlap of autoimmune hepatitis and primary biliary cirrhosis: long-term outcomes. *Am J Gastroenterol* 2007;102:1244–1250.
- [71] Joshi S, Cauch-Dudek K, Wanless IR, Lindor KD, Jorgensen R, Batts K, et al. Primary biliary cirrhosis with additional features of autoimmune hepatitis: response to therapy with ursodeoxycholic acid. *Hepatology* 2002;35:409–413.
- [72] Csepregi A, Rocken C, Treiber G, Malfertheiner P. Budesonide induces complete remission in autoimmune hepatitis. *World J Gastroenterol* 2006;12:1362–1366.
- [73] Duclos-Vallee JC, Hadengue A, Ganne-Carrie N, Robin E, Degott C, Erlinger S. Primary biliary cirrhosis–autoimmune hepatitis overlap syndrome. Corticoreistance and effective treatment by cyclosporine A. *Dig Dis Sci* 1995;40:1069–1073.
- [74] Maggs JR, Chapman RW. An update on primary sclerosing cholangitis. *Curr Opin Gastroenterol* 2008;24:377–383.
- [75] Karlsen TH, Schrumph E, Boberg KM. Genetic epidemiology of primary sclerosing cholangitis. *World J Gastroenterol* 2007;13:5421–5431.
- [76] Abdalian R, Heathcote EJ. Sclerosing cholangitis: a focus on secondary causes. *Hepatology* 2006;44:1063–1074.
- [77] Broome U, Olsson R, Loof L, Bodemar G, Hulterantz R, Danielsson A, et al. Natural history and prognostic factors in 305 Swedish patients with primary sclerosing cholangitis. *Gut* 1996;38:610–615.
- [78] Chapman RW, Arborgh BA, Rhodes JM, Summerfield JA, Dick R, Scheuer PJ, et al. Primary sclerosing cholangitis: a review of its clinical features, cholangiography, and hepatic histology. *Gut* 1980;21:870–877.
- [79] Tischendorf JJ, Hecker H, Kruger M, Manns MP, Meier PN. Characterization, outcome, and prognosis in 273 patients with primary sclerosing cholangitis: a single center study. *Am J Gastroenterol* 2007;102:107–114.
- [80] Boberg KM, Fausa O, Haaland T, Holter E, Mellbye OJ, Spurkland A, et al. Features of autoimmune hepatitis in primary sclerosing cholangitis: an evaluation of 114 primary sclerosing cholangitis patients according to a scoring system for the diagnosis of autoimmune hepatitis. *Hepatology* 1996;23:1369–1376.
- [81] Mendes FD, Jorgensen R, Keach J, Katzmann JA, Smyrk T, Donlinger J, et al. Elevated serum IgG4 concentration in patients with primary sclerosing cholangitis. *Am J Gastroenterol* 2006;101:2070–2075.
- [82] Hov JR, Boberg KM, Karlsen TH. Autoantibodies in primary sclerosing cholangitis. *World J Gastroenterol* 2008;14:3781–3791.
- [83] Ludwig J. Surgical pathology of the syndrome of primary sclerosing cholangitis. *Am J Surg Pathol* 1989;13:43–49.
- [84] van de Meeberg PC, Portincasa P, Wolfhagen FH, van Erpecum KJ, VanBerge-Henegouwen GP. Increased gall bladder volume in primary sclerosing cholangitis. *Gut* 1996;39:594–599.
- [85] Said K, Glaumann H, Bergquist A. Gallbladder disease in patients with primary sclerosing cholangitis. *J Hepatol* 2008;48:598–605.
- [86] Lee YM, Kaplan MM. Primary sclerosing cholangitis. *N Engl J Med* 1995;332:924–933.
- [87] MacCarty RL, LaRusso NF, Wiesner RH, Ludwig J. Primary sclerosing cholangitis: findings on cholangiography and pancreatography. *Radiology* 1983;149:39–44.
- [88] Bangarulingam SY, Gossard AA, Petersen BT, Ott BJ, Lindor KD. Complications of endoscopic retrograde cholangiopancreatography in primary sclerosing cholangitis. *Am J Gastroenterol* 2009;104:855–860.
- [89] Berstad AE, Aabakken L, Smith HJ, Aasen S, Boberg KM, Schrumph E. Diagnostic accuracy of magnetic resonance and endoscopic retrograde cholangiography in primary sclerosing cholangitis. *Clin Gastroenterol Hepatol* 2006;4:514–520.
- [90] Angulo P, Pearce DH, Johnson CD, Henry JJ, LaRusso NF, Petersen BT, et al. Magnetic resonance cholangiography in patients with biliary disease: its role in primary sclerosing cholangitis. *J Hepatol* 2000;33:520–527.
- [91] Bjornsson E, Olsson R, Bergquist A, Lindgren S, Braden B, Chapman RW, et al. The natural history of small-duct primary sclerosing cholangitis. *Gastroenterology* 2008;134:975–980.
- [92] Broome U, Glaumann H, Lindstrom E, Loof L, Almer S, Prytz H, et al. Natural history and outcome in 32 Swedish patients with small duct primary sclerosing cholangitis (PSC). *J Hepatol* 2002;36:586–589.
- [93] Angulo P, Maor-Kendler Y, Lindor KD. Small-duct primary sclerosing cholangitis: a long-term follow-up study. *Hepatology* 2002;35:1494–1500.
- [94] Bjornsson E, Boberg KM, Cullen S, Fleming K, Clausen OP, Fausa O, et al. Patients with small duct primary sclerosing cholangitis have a favourable long term prognosis. *Gut* 2002;51:731–735.
- [95] Gotthardt D, Runz H, Keitel V, Fischer C, Flechtenmacher C, Wirtenberger M, et al. A mutation in the canalicular phospholipid transporter gene, ABCB4, is associated with cholestasis, ductopenia, and cirrhosis in adults. *Hepatology* 2008;48:1157–1166.
- [96] Wilschanski M, Chait P, Wade JA, Davis L, Corey M, St. Louis P, et al. Primary sclerosing cholangitis in 32 children: clinical,

- laboratory, and radiographic features, with survival analysis. *Hepatology* 1995;22:1415–1422.
- [97] Feldstein AE, Perrault J, El-Youssif M, Lindor KD, Freese DK, Angulo P. Primary sclerosing cholangitis in children: a long-term follow-up study. *Hepatology* 2003;38:210–217.
- [98] Gregorio GV, Portmann B, Karani J, Harrison P, Donaldson PT, Vergani D, et al. Autoimmune hepatitis/sclerosing cholangitis overlap syndrome in childhood: a 16-year prospective study. *Hepatology* 2001;33:544–553.
- [99] Tanaka A, Takamori Y, Toda G, Ohnishi S, Takikawa H. Outcome and prognostic factors of 391 Japanese patients with primary sclerosing cholangitis. *Liver Int* 2008;28:983–989.
- [100] Loftus Jr EV, Harewood GC, Loftus CG, Tremaine WJ, Harmsen WS, Zinsmeister AR, et al. PSC-IBD: a unique form of inflammatory bowel disease associated with primary sclerosing cholangitis. *Gut* 2005;54:91–96.
- [101] Soetikno RM, Lin OS, Heidenreich PA, Young HS, Blackstone MO. Increased risk of colorectal neoplasia in patients with primary sclerosing cholangitis and ulcerative colitis: a meta-analysis. *Gastrointest Endosc* 2002;56:48–54.
- [102] Broome U, Bergquist A. Primary sclerosing cholangitis, inflammatory bowel disease, and colon cancer. *Semin Liver Dis* 2006;26:31–41.
- [103] Bergquist A, Ekblom A, Olsson R, Kornfeldt D, Loof L, Danielsson A, et al. Hepatic and extrahepatic malignancies in primary sclerosing cholangitis. *J Hepatol* 2002;36:321–327.
- [104] Lazaridis KN, Gores GJ. Primary sclerosing cholangitis and cholangiocarcinoma. *Semin Liver Dis* 2006;26:42–51.
- [105] Harnois DM, Gores GJ, Ludwig J, Steers JL, LaRusso NF, Wiesner RH. Are patients with cirrhotic stage primary sclerosing cholangitis at risk for the development of hepatocellular cancer? *J Hepatol* 1997;27:512–516.
- [106] Fevery J, Verslype C, Lai G, Aerts R, Van Steenberghe W. Incidence, diagnosis, and therapy of cholangiocarcinoma in patients with primary sclerosing cholangitis. *Dig Dis Sci* 2007;52:3123–3135.
- [107] Charatcharoenwitthaya P, Enders FB, Halling KC, Lindor KD. Utility of serum tumor markers, imaging, and biliary cytology for detecting cholangiocarcinoma in primary sclerosing cholangitis. *Hepatology* 2008;48:1106–1117.
- [108] Prytz H, Keiding S, Bjornsson E, Broome U, Almer S, Castedal M, et al. Dynamic FDG-PET is useful for detection of cholangiocarcinoma in patients with PSC listed for liver transplantation. *Hepatology* 2006;44:1572–1580.
- [109] Boberg KM, Jepsen P, Clausen OP, Foss A, Aabakken L, Schrupf E. Diagnostic benefit of biliary brush cytology in cholangiocarcinoma in primary sclerosing cholangitis. *J Hepatol* 2006;45:568–574.
- [110] Chazouilleres O, Poupon R, Capron JP, Metman EH, Dhumeaux D, Amouretti M, et al. Ursodeoxycholic acid for primary sclerosing cholangitis. *J Hepatol* 1990;11:120–123.
- [111] O'Brien CB, Senior JR, Arora-Mirchandani R, Batta AK, Salen G. Ursodeoxycholic acid for the treatment of primary sclerosing cholangitis: a 30-month pilot study. *Hepatology* 1991;14:838–847.
- [112] Beuers U, Spengler U, Kruis W, Aydemir U, Wiebecke B, Heldwein W, et al. Ursodeoxycholic acid for treatment of primary sclerosing cholangitis: a placebo-controlled trial. *Hepatology* 1992;16:707–714.
- [113] Stiehl A. Ursodeoxycholic acid therapy in treatment of primary sclerosing cholangitis. *Scand J Gastroenterol Suppl* 1994;204:59–61.
- [114] Lindor KD. Ursodiol for primary sclerosing cholangitis. Mayo Primary Sclerosing Cholangitis-Ursodeoxycholic Acid Study Group. *N Engl J Med* 1997;336:691–695.
- [115] Mitchell SA, Bansi DS, Hunt N, Von Bergmann K, Fleming KA, Chapman RW. A preliminary trial of high-dose ursodeoxycholic acid in primary sclerosing cholangitis. *Gastroenterology* 2001;121:900–907.
- [116] Cullen SN, Rust C, Fleming K, Edwards C, Beuers U, Chapman R. High dose ursodeoxycholic acid for the treatment of primary sclerosing cholangitis is safe and effective. *J Hepatol* 2008;48:792–800.
- [117] Olsson R, Boberg KM, de Muckadell OS, Lindgren S, Hultcrantz R, Folvik G, et al. High-dose ursodeoxycholic acid in primary sclerosing cholangitis: a 5-year multicenter, randomized, controlled study. *Gastroenterology* 2005;129:1464–1472.
- [118] Lindor KD, Enders FB, Schmoll JA, Hoskin TL, Jorgensen RA, Petz JL, et al. Randomized, double-blind controlled trial of high-dose ursodeoxycholic acid for primary sclerosing cholangitis. *Hepatology* 2008;48:378A.
- [119] Tung BY, Emond MJ, Haggitt RC, Bronner MP, Kimmey MB, Kowdley KV, et al. Ursodiol use is associated with lower prevalence of colonic neoplasia in patients with ulcerative colitis and primary sclerosing cholangitis. *Ann Intern Med* 2001;134:89–95.
- [120] Wolf JM, Rybicki LA, Lashner BA. The impact of ursodeoxycholic acid on cancer, dysplasia and mortality in ulcerative colitis patients with primary sclerosing cholangitis. *Aliment Pharmacol Ther* 2005;22:783–788.
- [121] Pardi DS, Loftus Jr EV, Kremers WK, Keach J, Lindor KD. Ursodeoxycholic acid as a chemopreventive agent in patients with ulcerative colitis and primary sclerosing cholangitis. *Gastroenterology* 2003;124:889–893.
- [122] Rudolph G, Kloeters-Plachky P, Rost D, Stiehl A. The incidence of cholangiocarcinoma in primary sclerosing cholangitis after long-time treatment with ursodeoxycholic acid. *Eur J Gastroenterol Hepatol* 2007;19:487–491.
- [123] Brandsaeter B, Isoniemi H, Broome U, Olausson M, Backman L, Hansen B, et al. Liver transplantation for primary sclerosing cholangitis: predictors and consequences of hepatobiliary malignancy. *J Hepatol* 2004;40:815–822.
- [124] Boberg KM, Egeland T, Schrupf E. Long-term effect of corticosteroid treatment in primary sclerosing cholangitis patients. *Scand J Gastroenterol* 2003;38:991–995.
- [125] Etzel JP, Eng SC, Ko CW, Lee SD, Saunders MD, Tung BY, et al. Complications after ERCP in patients with primary sclerosing cholangitis. *Gastrointest Endosc* 2008;67:643–648.
- [126] Andriulli A, Loperfido S, Napolitano G, Niro G, Valvano MR, Spirito F, et al. Incidence rates of post-ERCP complications: a systematic survey of prospective studies. *Am J Gastroenterol* 2007;102:1781–1788.
- [127] van den Hazel SJ, Wolfhagen EH, van Buuren HR, van de Meeberg PC, Van Leeuwen DJ. Prospective risk assessment of endoscopic retrograde cholangiography in patients with primary sclerosing cholangitis. Dutch PSC Study Group. *Endoscopy* 2000;32:779–782.
- [128] Bjornsson E, Lindqvist-Ottosson J, Asztely M, Olsson R. Dominant strictures in patients with primary sclerosing cholangitis. *Am J Gastroenterol* 2004;99:502–508.
- [129] Hammel P, Couvelard A, O'Toole D, Ratouis A, Sauvanet A, Flejou JF, et al. Regression of liver fibrosis after biliary drainage in patients with chronic pancreatitis and stenosis of the common bile duct. *N Engl J Med* 2001;344:418–423.
- [130] Stiehl A, Rudolph G, Kloeters-Plachky P, Sauer P, Walker S. Development of dominant bile duct stenoses in patients with primary sclerosing cholangitis treated with ursodeoxycholic acid: outcome after endoscopic treatment. *J Hepatol* 2002;36:151–156.
- [131] Baluyut AR, Sherman S, Lehman GA, Hoen H, Chalasani N. Impact of endoscopic therapy on the survival of patients with primary sclerosing cholangitis. *Gastrointest Endosc* 2001;53:308–312.

- [132] Johnson GK, Geenen JE, Venu RP, Schmalz MJ, Hogan WJ. Endoscopic treatment of biliary tract strictures in sclerosing cholangitis: a larger series and recommendations for treatment. *Gastrointest Endosc* 1991;37:38–43.
- [133] Stiehl A, Rudolph G, Sauer P, Benz C, Stremmel W, Walker S, et al. Efficacy of ursodeoxycholic acid treatment and endoscopic dilation of major duct stenoses in primary sclerosing cholangitis. An 8-year prospective study. *J Hepatol* 1997;26:560–566.
- [134] van Milligen de Wit AW, Rauws EA, van Bracht J, Mulder CJ, Jones EA, Tytgat GN, et al. Lack of complications following short-term stent therapy for extrahepatic bile duct strictures in primary sclerosing cholangitis. *Gastrointest Endosc* 1997;46:344–347.
- [135] Kaya M, Petersen BT, Angulo P, Baron TH, Andrews JC, Gostout CJ, et al. Balloon dilation compared to stenting of dominant strictures in primary sclerosing cholangitis. *Am J Gastroenterol* 2001;96:1059–1066.
- [136] Welsh FK, Wigmore SJ. Roux-en-Y choledochojejunostomy is the method of choice for biliary reconstruction in liver transplantation for primary sclerosing cholangitis. *Transplantation* 2004;77:602–604.
- [137] Gordon F. Recurrent primary sclerosing cholangitis: clinical diagnosis and long-term management issues. *Liver Transpl* 2006;12:S73–S75.
- [138] LaRusso NF, Shneider BL, Black D, Gores GJ, James SP, Doo E, et al. Primary sclerosing cholangitis: summary of a workshop. *Hepatology* 2006;44:746–764.
- [139] Cholongitas E, Shusang V, Papatheodoridis GV, Marelli L, Manousou P, Rolando N, et al. Risk factors for recurrence of primary sclerosing cholangitis after liver transplantation. *Liver Transpl* 2008;14:138–143.
- [140] el-Shabrawi M, Wilkinson ML, Portmann B, Mieli-Vergani G, Chong SK, Williams R, et al. Primary sclerosing cholangitis in childhood. *Gastroenterology* 1987;92:1226–1235.
- [141] Minuk GY, Sutherland LR, Pappas G, Kelly JK, Martin SE. Autoimmune chronic active hepatitis (lupoid hepatitis) and primary sclerosing cholangitis in two young adult females. *Can J Gastroenterol* 1988;2:22–27.
- [142] Rabinovitz M, Demetris AJ, Bou-Abboud CF, Van Thiel DH. Simultaneous occurrence of primary sclerosing cholangitis and autoimmune chronic active hepatitis in a patient with ulcerative colitis. *Dig Dis Sci* 1992;37:1606–1611.
- [143] Lawrence SP, Sherman KE, Lawson JM, Goodman ZD. A 39 year old man with chronic hepatitis. *Semin Liver Dis* 1994;14:97–105.
- [144] Debray D, Pariente D, Urvoas E, Hadchouel M, Bernard O. Sclerosing cholangitis in children. *J Pediatr* 1994;124:49–56.
- [145] Wilschanski M, Chait P, Wade JA, Davis L, Corey M, St. Louis P, et al. Primary sclerosing cholangitis in 32 children: clinical, laboratory, and radiographic features, with survival analysis. *Hepatology* 1995;22:1415–1422.
- [146] Gohlke F, Lohse AW, Dienes HP, Lohr H, Marker-Hermann E, Gerken G, et al. Evidence for an overlap syndrome of autoimmune hepatitis and primary sclerosing cholangitis. *J Hepatol* 1996;24:699–705.
- [147] McNair AN, Moloney M, Portmann BC, Williams R, McFarlane IG. Autoimmune hepatitis overlapping with primary sclerosing cholangitis in five cases. *Am J Gastroenterol* 1998;93:777–784.
- [148] Al-Chalabi T, Portmann BC, Bernal W, McFarlane IG, Henehan MA. Autoimmune hepatitis overlap syndromes: an evaluation of treatment response, long-term outcome and survival. *Aliment Pharmacol Ther* 2008;28:209–220.
- [149] van Buuren HR, van Hoogstraten HJE, Terkivatan T, Schalm SW, Vleggaar FP. High prevalence of autoimmune hepatitis among patients with primary sclerosing cholangitis. *J Hepatol* 2000;33:543–548.
- [150] Kaya M, Angulo P, Lindor KD. Overlap of autoimmune hepatitis and primary sclerosing cholangitis: an evaluation of a modified scoring system. *J Hepatol* 2000;33:537–542.
- [151] Floreani A, Rizzotto ER, Ferrara F, Carderi I, Caroli D, Blasone L, et al. Clinical course and outcome of autoimmune hepatitis/primary sclerosing cholangitis overlap syndrome. *Am J Gastroenterol* 2005;100:1516–1522.
- [152] Abdo AA, Bain VG, Kichian K, Lee SS. Evolution of autoimmune hepatitis to primary sclerosing cholangitis: a sequential syndrome. *Hepatology* 2002;36:1393–1399.
- [153] Stathopoulos G, Nourmand AD, Blackstone M, Andersen D, Baker AL. Rapidly progressive sclerosing cholangitis following surgical treatment of pancreatic pseudotumor. *J Clin Gastroenterol* 1995;21:143–148.
- [154] Erkelens GW, Vleggaar FP, Lesterhuis W, van Buuren HR, van der Werf SD. Sclerosing pancreato-cholangitis responsive to steroid therapy. *Lancet* 1999;354:43–44.
- [155] van Buuren HR, Vleggaar FP, Willemien Erkelens G, Zondervan PE, Lesterhuis W, Van Eijck CH, et al. Autoimmune pancreatocholangitis: a series of ten patients. *Scand J Gastroenterol Suppl* 2006;243:70–78.
- [156] Bjornsson E, Chari ST, Smyrk TC, Lindor K. Immunoglobulin G4 associated cholangitis: description of an emerging clinical entity based on review of the literature. *Hepatology* 2007;45:1547–1554.
- [157] Umemura T, Zen Y, Hamano H, Kawa S, Nakanuma Y, Kiyosawa K. Immunoglobulin G4-hepatopathy: association of immunoglobulin G4-bearing plasma cells in liver with autoimmune pancreatitis. *Hepatology* 2007;46:463–471.
- [158] Zen Y, Fujii T, Harada K, Kawano M, Yamada K, Takahira M, et al. Th2 and regulatory immune reactions are increased in immunoglobulin G4-related sclerosing pancreatitis and cholangitis. *Hepatology* 2007;45:1538–1546.
- [159] Ghazale A, Chari ST, Zhang L, Smyrk TC, Takahashi N, Levy MJ, et al. Immunoglobulin G4-associated cholangitis: clinical profile and response to therapy. *Gastroenterology* 2008;134:706–715.
- [160] Colombo C, Battezzati PM, Crosignani A, Morabito A, Costantini D, Padoan R, et al. Liver disease in cystic fibrosis: a prospective study on incidence, risk factors, and outcome. *Hepatology* 2002;36:1374–1382.
- [161] Sokol RJ, Durie PR. Recommendations for management of liver and biliary tract disease in cystic fibrosis. Cystic Fibrosis Foundation Hepatobiliary Disease Consensus Group. *J Pediatr Gastroenterol Nutr* 1999;28:S1–S13.
- [162] Colombo C, Battezzati PM, Podda M, Bettinardi N, Giunta A. Ursodeoxycholic acid for liver disease associated with cystic fibrosis: a double-blind multicenter trial. The Italian Group for the Study of Ursodeoxycholic Acid in Cystic Fibrosis. *Hepatology* 1996;23:1484–1490.
- [163] van de Meeberg PC, Houwen RH, Sinaasappel M, Heijerman HG, Bijleveld CM, Vanberge-Henegouwen GP. Low-dose versus high-dose ursodeoxycholic acid in cystic fibrosis-related cholestatic liver disease. Results of a randomized study with 1-year follow-up. *Scand J Gastroenterol* 1997;32:369–373.
- [164] Lindblad A, Glaumann H, Strandvik B. A two-year prospective study of the effect of ursodeoxycholic acid on urinary bile acid excretion and liver morphology in cystic fibrosis-associated liver disease. *Hepatology* 1998;27:166–174.
- [165] Debray D, Lykavieris P, Gauthier F, Dousset B, Sardet A, Munck A, et al. Outcome of cystic fibrosis-associated liver cirrhosis: management of portal hypertension. *J Hepatol* 1999;31:77–83.
- [166] Oude Elferink RP, Paulusma CC, Groen AK. Hepatocanalicular transport defects: pathophysiologic mechanisms of rare diseases. *Gastroenterology* 2006;130:908–925.
- [167] de Vree JM, Jacquemin E, Sturm E, Cresteil D, Bosma PJ, Aten J, et al. Mutations in the MDR3 gene cause progressive familial

- intrahepatic cholestasis. *Proc Natl Acad Sci USA* 1998;95:282–287.
- [168] Paulusma CC, Groen A, Kunne C, Ho-Mok KS, Spijkerboer AL, Rudi de Waart D, et al. Atp8b1 deficiency in mice reduces resistance of the canalicular membrane to hydrophobic bile salts and impairs bile salt transport. *Hepatology* 2006;44:195–204.
- [169] Strautnieks SS, Bull LN, Knisely AS, Kocoshis SA, Dahl N, Arnell H, et al. A gene encoding a liver-specific ABC transporter is mutated in progressive familial intrahepatic cholestasis. *Nat Genet* 1998;20:233–238.
- [170] Knisely AS, Strautnieks SS, Meier Y, Stieger B, Byrne JA, Portmann BC, et al. Hepatocellular carcinoma in ten children under five years of age with bile salt export pump deficiency. *Hepatology* 2006;44:478–486.
- [171] Trauner M, Fickert P, Wagner M. MDR3 (ABCB4) defects: a paradigm for the genetics of adult cholestatic syndromes. *Semin Liver Dis* 2007;27:77–98.
- [172] Jacquemin E. Role of multidrug resistance 3 deficiency in pediatric and adult liver disease: one gene for three diseases. *Semin Liver Dis* 2001;21:551–562.
- [173] Whittington PF, Whittington GL. Partial external diversion of bile for the treatment of intractable pruritus associated with intrahepatic cholestasis. *Gastroenterology* 1988;95:130–136.
- [174] Arnell H, Bergdahl S, Papadogiannakis N, Nemeth A, Fischler B. Preoperative observations and short-term outcome after partial external biliary diversion in 13 patients with progressive familial intrahepatic cholestasis. *J Pediatr Surg* 2008;43:1312–1320.
- [175] van Ooteghem NA, Klomp LW, van Berge-Henegouwen GP, Houwen RH. Benign recurrent intrahepatic cholestasis progressing to progressive familial intrahepatic cholestasis: low GGT cholestasis is a clinical continuum. *J Hepatol* 2002;36:439–443.
- [176] Stapelbroek JM, van Erpecum KJ, Klomp LW, Venneman NG, Schwartz TP, van Berge Henegouwen GP, et al. Nasobiliary drainage induces long-lasting remission in benign recurrent intrahepatic cholestasis. *Hepatology* 2006;43:51–53.
- [177] Piccoli DA, Spinner NB. Alagille syndrome and the Jagged1 gene. *Semin Liver Dis* 2001;21:525–534.
- [178] Benichou C. Criteria of drug-induced liver disorders. Report of an international consensus meeting. *J Hepatol* 1990;11:272–276.
- [179] Andrade RJ, Lucena MI, Fernandez MC, Pelaez G, Pachkoria K, Garcia-Ruiz E, et al. Drug-induced liver injury: an analysis of 461 incidences submitted to the Spanish registry over a 10-year period. *Gastroenterology* 2005;129:512–521.
- [180] Kaplowitz N. Idiosyncratic drug hepatotoxicity. *Nat Rev Drug Discov* 2005;4:489–499.
- [181] Marschall HU, Wagner M, Zollner G, Trauner M. Clinical hepatotoxicity. Regulation and treatment with inducers of transport and cofactors. *Mol Pharm* 2007;4:895–910.
- [182] Maddrey WC. Drug-induced hepatotoxicity: 2005. *J Clin Gastroenterol* 2005;39:S83–S89.
- [183] Erlinger S. Drug-induced cholestasis. *J Hepatol* 1997;26:S1–S4.
- [184] Navarro VJ, Senior JR. Drug-related hepatotoxicity. *N Engl J Med* 2006;354:731–739.
- [185] Nathwani RA, Kaplowitz N. Drug hepatotoxicity. *Clin Liver Dis* 2006;10:207–217.
- [186] Aithal PG, Day CP. The natural history of histologically proved drug induced liver disease. *Gut* 1999;44:731–735.
- [187] Desmet VJ. Vanishing bile duct syndrome in drug-induced liver disease. *J Hepatol* 1997;26:S31–S35.
- [188] Lammert F, Marschall HU, Glantz A, Matern S. Intrahepatic cholestasis of pregnancy: molecular pathogenesis, diagnosis and management. *J Hepatol* 2000;33:1012–1021.
- [189] Pusch T, Beuers U. Intrahepatic cholestasis of pregnancy. *Orphanet J Rare Dis* 2007;2:26.
- [190] Glantz A, Marschall HU, Mattsson LA. Intrahepatic cholestasis of pregnancy: relationships between bile acid levels and fetal complication rates. *Hepatology* 2004;40:467–474.
- [191] Royal College of Obstetricians and Gynaecologists. Obstetric cholestasis. RCOG Guideline No. 43, 2006:1–10.
- [192] Brites D. Intrahepatic cholestasis of pregnancy: changes in maternal-fetal bile acid balance and improvement by ursodeoxycholic acid. *Ann Hepatol* 2002;1:20–28.
- [193] Palma J, Reyes H, Ribalta J, Hernandez I, Sandoval L, Almuna R, et al. Ursodeoxycholic acid in the treatment of cholestasis of pregnancy: a randomized, double-blind study controlled with placebo. *J Hepatol* 1997;27:1022–1028.
- [194] Williamson C, Hems LM, Goulis DG, Walker I, Chambers J, Donaldson O, et al. Clinical outcome in a series of cases of obstetric cholestasis identified via a patient support group. *BJOG* 2004;111:676–681.
- [195] Lee RH, Kwok KM, Ingles S, Wilson ML, Mullin P, Incerpi M, et al. Pregnancy outcomes during an era of aggressive management for intrahepatic cholestasis of pregnancy. *Am J Perinatol* 2008;25:341–345.
- [196] Hay JE. Liver disease in pregnancy. *Hepatology* 2008;47:1067–1076.
- [197] Glantz A, Marschall HU, Lammert F, Mattsson LA. Intrahepatic cholestasis of pregnancy: a randomized controlled trial comparing dexamethasone and ursodeoxycholic acid. *Hepatology* 2005;42:1399–1405.
- [198] Kondrackiene J, Beuers U, Kupcinskas L. Efficacy and safety of ursodeoxycholic acid versus cholestyramine in intrahepatic cholestasis of pregnancy. *Gastroenterology* 2005;129:894–901.
- [199] Binder T, Salaj P, Zima T, Vitek L. Randomized prospective comparative study of ursodeoxycholic acid and S-adenosyl-L-methionine in the treatment of intrahepatic cholestasis of pregnancy. *J Perinat Med* 2006;34:383–391.
- [200] Roncaglia N, Locatelli A, Arreghini A, Assi F, Camerani I, Pezzullo JC, et al. A randomized controlled trial of ursodeoxycholic acid and S-adenosyl-L-methionine in the treatment of gestational cholestasis. *BJOG* 2004;111:17–21.
- [201] Mazzella G, Nicola R, Francesco A, Patrizia S, Luciano B, Anna M, et al. Ursodeoxycholic acid administration in patients with cholestasis of pregnancy: effects on primary bile acids in babies and mothers. *Hepatology* 2001;33:504–508.
- [202] Kenyon AP, Piercy CN, Girling J, Williamson C, Tribe RM, Shennan AH. Obstetric cholestasis, outcome with active management: a series of 70 cases. *BJOG* 2002;109:282–288.
- [203] Roncaglia N, Arreghini A, Locatelli A, Bellini P, Andreotti C, Ghidini A. Obstetric cholestasis: outcome with active management. *Eur J Obstet Gynecol Reprod Biol* 2002;100:167–170.
- [204] Ko CW, Beresford SA, Schulte SJ, Matsumoto AM, Lee SP. Incidence, natural history, and risk factors for biliary sludge and stones during pregnancy. *Hepatology* 2005;41:359–365.
- [205] Kahaleh M, Hartwell GD, Arseneau KO, Pajewski TN, Mullick T, Isin G, et al. Safety and efficacy of ERCP in pregnancy. *Gastrointest Endosc* 2004;60:287–292.
- [206] Tham TC, Vandervoort J, Wong RC, Montes H, Roston AD, Slivka A, et al. Safety of ERCP during pregnancy. *Am J Gastroenterol* 2003;98:308–311.
- [207] Cohen LB, Delege MH, Aisenberg J, Brill JV, Inadomi JM, Kochman ML, et al. AGA Institute review of endoscopic sedation. *Gastroenterology* 2007;133:675–701.
- [208] Mahadevan U, Kane S. American gastroenterological association institute technical review on the use of gastrointestinal medications in pregnancy. *Gastroenterology* 2006;131:283–311.
- [209] Poupon R, Chretien Y, Chazouilleres O, Poupon RE. Pregnancy in women with ursodeoxycholic acid-treated primary biliary cirrhosis. *J Hepatol* 2005;42:418–419.

- [210] Hempfling W, Dilger K, Beuers U. Systematic review: ursodeoxycholic acid—adverse effects and drug interactions. *Aliment Pharmacol Ther* 2003;18:963–972.
- [211] Park-Wyllie L, Mazzotta P, Pastuszak A, Moretti ME, Beique L, Hunnisett L, et al. Birth defects after maternal exposure to corticosteroids: prospective cohort study and meta-analysis of epidemiological studies. *Teratology* 2000;62:385–392.
- [212] Armenti VT, Moritz MJ, Cardonick EH, Davison JM. Immunosuppression in pregnancy: choices for infant and maternal health. *Drugs* 2002;62:2361–2375.
- [213] Benjaminov FS, Heathcote J. Liver disease in pregnancy. *Am J Gastroenterol* 2004;99:2479–2488.
- [214] Kremer AE, Beuers U, Oude-Elferink RP, Puhl T. Pathogenesis and treatment of pruritus in cholestasis. *Drugs* 2008;68:2163–2182.
- [215] Datta DV, Sherlock S. Cholestyramine for long term relief of the pruritus complicating intrahepatic cholestasis. *Gastroenterology* 1966;50:323–332.
- [216] Rust C, Sauter GH, Oswald M, Buttner J, Kullak-Ublick GA, Paumgartner G, et al. Effect of cholestyramine on bile acid patterns and synthesis during administration of ursodeoxycholic acid in man. *Eur J Clin Invest* 2000;30:135–139.
- [217] Khurana S, Singh P. Rifampin is safe for the treatment of pruritus due to chronic cholestasis: a meta-analysis of prospective randomized-controlled trials. *Liver Int* 2006;26:943–948.
- [218] Tandon P, Rowe BH, Vandermeer B, Bain VG. The efficacy and safety of bile acid binding agents, opioid antagonists or rifampicin in the treatment of cholestasis-associated pruritus. *Am J Gastroenterol* 2007;102:1528–1536.
- [219] Bachs L, Pares A, Elena M, Piera C, Rodes J. Effects of long-term rifampicin administration in primary biliary cirrhosis. *Gastroenterology* 1992;102:2077–2080.
- [220] Prince MI, Burt AD, Jones DEJ. Hepatitis and liver dysfunction with rifampicin therapy for pruritus in primary biliary cirrhosis. *Gut* 2002;50:436–439.
- [221] Jones EA, Dekker RL. Florid opioid withdrawal-like reaction precipitated by naltrexone in a patient with chronic cholestasis. *Gastroenterology* 2000;118:431–432.
- [222] Jones EA, Neuberger JM, Bergasa NV. Opiate antagonist therapy for the pruritus of cholestasis: the avoidance of opioid withdrawal-like reactions. *Q J Med* 2002;95:547–552.
- [223] Mayo MJ, Handem I, Saldana S, Jacobs H, Getachew Y, Rush AJ. Sertraline as a first-line treatment for cholestatic pruritus. *Hepatology* 2007;45:666–674.
- [224] Pares A, Cisneros L, Salmeron JM, Caballeria L, Mas A, Torras A, et al. Extracorporeal albumin dialysis: a procedure for prolonged relief of intractable pruritus in patients with primary biliary cirrhosis. *Am J Gastroenterol* 2004;99:1105–1110.
- [225] Puhl T, Denk GU, Parhofer KG, Beuers U. Plasma separation and anion adsorption transiently relieve intractable pruritus in primary biliary cirrhosis. *J Hepatol* 2006;45:887–891.
- [226] Alallam A, Barth D, Heathcote EJ. Role of plasmapheresis in the treatment of severe pruritus in pregnant patients with primary biliary cirrhosis: case reports. *Can J Gastroenterol* 2008;22:505–507.
- [227] Beuers U, Gerken G, Puhl T. Biliary drainage transiently relieves intractable pruritus in primary biliary cirrhosis. *Hepatology* 2006;44:280–281.
- [228] Gross CR, Malinchoc M, Kim WR, Evans RW, Wiesner RH, Petz JL, et al. Quality of life before and after liver transplantation for cholestatic liver disease. *Hepatology* 1999;29:356–364.
- [229] Jones DEJ. Fatigue in cholestatic liver disease: is it all in the mind? *J Hepatol* 2007;46:992–994.
- [230] Newton JL, Pairman J, Sutcliffe K, Wilton K, Jones DEJ. A predictive model for fatigue and its aetiological associations in primary biliary cirrhosis. *Clin Gastroenterol Hepatol* 2008;6:228–233.
- [231] Newton JL, Gibson JG, Tomlinson M, Wilton K, Jones DEJ. Fatigue in primary biliary cirrhosis is associated with excessive daytime somnolence. *Hepatology* 2006;44:91–98.
- [232] Jones DE, Newton JL. An open study of modafinil for the treatment of daytime somnolence and fatigue in primary biliary cirrhosis. *Aliment Pharmacol Ther* 2007;25:471–476.
- [233] Ian Gan S, de Jongh M, Kaplan MM. Modafinil in the treatment of debilitating fatigue in primary biliary cirrhosis: a clinical experience. *Dig Dis Sci* 2008 Dec 12. [Epub ahead of print].
- [234] Jones DEJ, Sutcliffe K, Pairman J, Wilton K, Newton JL. An integrated care pathway improves quality of life in primary biliary cirrhosis. *QJM* 2008;101:535–543.
- [235] Pares A, Guanabens N. Osteoporosis in primary biliary cirrhosis: pathogenesis and treatment. *Clin Liver Dis* 2008;12:407–424.
- [236] Pereira SP, O'Donohue J, Moniz C, Phillips MG, Abrahá H, Buxton-Thomas M, et al. Transdermal hormone replacement therapy improves vertebral bone density in primary biliary cirrhosis: results of a 1-year controlled trial. *Aliment Pharmacol Therap* 2004;19:563–570.
- [237] Boone RH, Cheung AM, Gurlan M, Heathcote EJ. Osteoporosis in primary biliary cirrhosis: a randomized trial of the efficacy and feasibility of estrogen/progestin. *Dig Dis Sci* 2006;51:1103–1112.
- [238] Guanabens N, Pares A, Ros I, Alvarez L, Pons F, Caballeria L, et al. Alendronate is more effective than etidronate for increasing bone mass in osteopenic patients with primary biliary cirrhosis. *Am J Gastroenterol* 2003;98:2268–2274.
- [239] Musialik J, Petelenz M, Gonciarz Z. Effects of alendronate on bone mass in patients with primary biliary cirrhosis and osteoporosis: preliminary results after one year. *Scand J Gastroenterol* 2005;40:873–874.
- [240] Guanabens N, Pares A, del Rio L, Roca M, Gomez R, Munoz J, et al. Sodium fluoride prevents bone loss in primary biliary cirrhosis. *J Hepatol* 1992;15:345–349.
- [241] Levy C, Harnois DM, Angulo P, Jorgensen R, Lindor KD. Raloxifene improves bone mass in osteopenic women with primary biliary cirrhosis: results of a pilot study. *Liver Int* 2005;25:117–121.
- [242] Newton JL, Francis R, Prince M, James OFW, Bassendine MF, Rawlings D, et al. Osteoporosis in primary biliary cirrhosis revisited. *Gut* 2001;49:282–287.
- [243] Gores GJ, Wiesner RH, Dickson ER, Zinsmeister AR, Jorgensen RA, Langworthy A. Prospective evaluation of esophageal varices in primary biliary cirrhosis: development, natural history, and influence on survival. *Gastroenterology* 1989;96:1552–1559.
- [244] Jones DEJ, Metcalf JV, Collier JD, Bassendine MF, James OFW. Hepatocellular carcinoma in primary biliary cirrhosis and its impact on outcomes. *Hepatology* 1997;26:1138–1142.
- [245] Garcia-Tsao G, Sanyal AJ, Grace ND, Carey W. Prevention and management of gastroesophageal varices and variceal hemorrhage in cirrhosis. *Hepatology* 2007;46:922–938.
- [246] Bruix J, Sherman M. Management of hepatocellular carcinoma. *Hepatology* 2005;42:1208–1236.
- [247] Bressler B, Pinto R, El-Ashry D, Heathcote EJ. Which patients with primary biliary cirrhosis or primary sclerosing cholangitis should undergo endoscopic screening for oesophageal varices detection. *Gut* 2005;54:407–410.