

# **Ankle Block**

William F. Urmev, MD

Assistant Professor Clinical Anesthesiology

Hospital for Special Surgery, Weill Medical College of Cornell University

New York, NY

Ankle block can be used to provide reliable anesthesia for foot surgery.<sup>1</sup> Major clinical attributes of the ankle block include its being 1) technically easy to perform and teach<sup>2</sup> 2) characterized by a success rate near 100%<sup>3</sup> 3) devoid of major physiological perturbations associated with axial or more central blocks<sup>4</sup> 4) associated with very low plasma levels of local anesthetic 5) associated with an ability to ambulate immediately following surgery 6) able to produce extended analgesia up to 48 hours by single injections and 7) extremely safe with almost no risk of serious complications. Disadvantages include 1) the inability to use a proximal (thigh or calf) tourniquet for extended periods and 2) lack of blockade of the extrinsic muscles of the foot.

Ankle block is performed by a combination of direct perineural injections and field block to achieve sensory and motor blockade of the five terminal peripheral nerves to the foot. The conventional ankle block above the malleoli is more difficult to perform and has a lower associated clinical success rate. Midtarsal block, first described by Sharrock is easier to perform and the success rate approaches 100%.<sup>2</sup> This discussion will concentrate on this author's modification of midtarsal block.

## **Relevant Anatomy**

The five peripheral nerves that supply innervation to the foot are the terminal branches of the sciatic and femoral nerves. The sciatic nerve gives rise to the posterior tibial, deep peroneal, superficial peroneal, and sural nerves. The femoral nerve terminates in the saphenous nerve.

The posterior tibial nerve originates from the tibial nerve. It passes medial to the flexor hallucis longus tendon and is just posterior to the posterior tibial artery, posterior to the medial malleolus. The posterior tibial nerve lies deep to the flexor retinaculum. Because of this, it is the nerve most commonly missed by novices performing ankle block. The nerve courses more

superficially above the retinaculum distal to the medial malleolus at the midfoot or midtarsal area. The posterior tibial nerve supplies innervation to the medial and plantar surfaces of the foot.

The deep peroneal nerve is the terminal portion of the common peroneal nerve and runs with the anterior tibial artery. Similar to the posterior tibial nerve, it can be blocked by using a perivascular approach with the dorsalis pedis artery serving as a landmark. The deep peroneal nerve is also characterized by being more superficial at the midtarsal location, and therefore easier to block at that point than above the malleoli. It supplies innervation to the deep dorsal part of the foot and to the web space between the great toe and second toe.

The superficial peroneal nerve also comes from the common peroneal nerve to supply the dorsal part of the foot. It runs subcutaneously and is blocked by a “field block” approach.

Of the five nerves blocked, only the saphenous nerve arises from the femoral nerve. The ability to block the saphenous nerve is of use when performing sciatic nerve block for foot surgery as well as when ankle block is chosen. It supplies sensory innervation to the medial superficial foot. The saphenous nerve runs subcutaneously. This, coupled with its variable anatomical position, makes it ideal for field block.

The sural nerve arises from the tibial nerve and is characterized by a subcutaneous, variable anatomical location posterior to the lateral malleolus and anterior to the achilles tendon. It supplies innervation to the lateral foot, including the fifth toe. The sural nerve, too, is suited to easy block by subcutaneous field block.

### **Midtarsal Block Technique and Clinical Considerations**

The use of judicious amounts of intravenous sedation is recommended. Subcutaneous local anesthetic injection during ankle block is associated with some discomfort. Administration of a benzodiazepene intravenously before block improves patient tolerance and acceptance.

The two larger nerves (deep peroneal and posterior tibial nerve) are blocked first to decrease total onset time. Using the dorsalis pedis pulse as a landmark at the midtarsal location, a 23-gauge or 25-gauge 2.5 cm needle is inserted immediately lateral to the artery (Figure 1). The tip of the needle is advanced to the subcutaneous layer directly or advanced to bone contact and retracted to

½ the distance to the skin. Following negative aspiration, 5-7 mL local anesthetic is injected. Swelling should be observed longitudinally along the neurovascular axis. If dermal tension or skin blanching is observed, the needle is likely to be intradermal and should be advanced deeper.

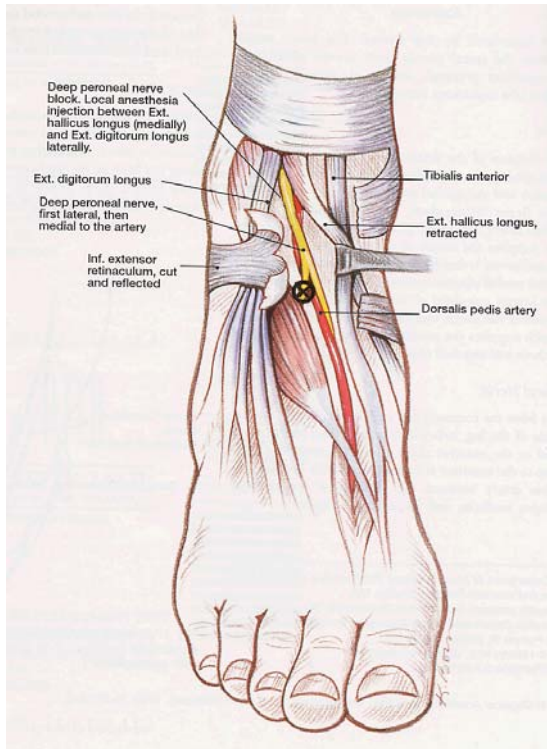


Figure 1: Deep peroneal nerve and site of deep peroneal nerve block. Adapted from Concepcion M. Ankle block. *Tech Reg Anesth Pain Med* 1999; 3: 241.

The posterior tibial nerve is now anesthetized by rotating the foot laterally. The pulse of the artery is palpated and used as a landmark. The needle is inserted immediately posterior to the artery into the subcutaneous tissues. Following negative aspiration, 5-7 mL of local anesthetic is injected. As with the deep peroneal nerve, swelling should be observed with injection. The needle is now redirected in the direction of the great toe and an additional 3-5 mL is injected (Figure 2). If either dorsalis pedis or posterior tibial artery is not palpable, a Doppler probe can be used to locate the artery. Alternatively, percutaneous electrode guidance (PEG)<sup>5</sup>, using the transcutaneous electrode to elicit plantar flexions, can be used to locate and inject the posterior tibial nerve. It is important that the needle is deep to the retinaculum when injecting posterior to the malleolus. Supplementation by the surgeon can be easily performed if any nerve block is inadequate.

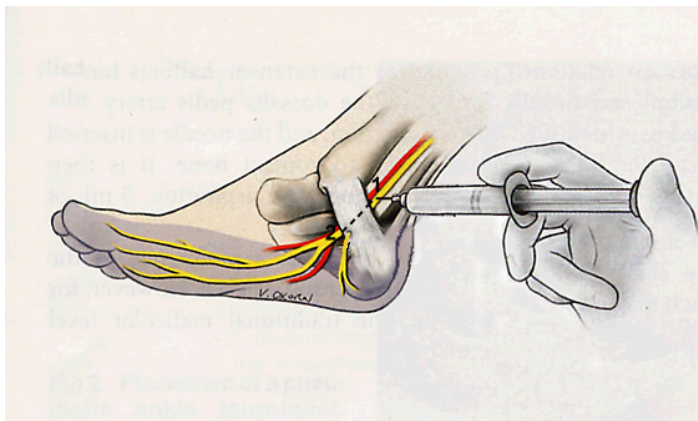


Figure 2: Anesthetizing the posterior tibial nerve. Adapted from Kay J. Ankle block. *Tech Reg Anesth Pain Med* 1999; 3: 3.

Field block of the remaining three nerves, saphenous, superficial peroneal, and sural are now performed. A 27-gauge, 4 cm needle is inserted into the area previously anesthetized during deep peroneal nerve block. The subcutaneous plane is identified when the needle freely glides. The entire length of the needle is guided in this plane toward the post tibial nerve injection site. Injection is made slowly upon needle withdrawal. Swelling without skin blanching should be observed. If swelling is not seen, the needle tip is too deep. This technique is used to “connect the dots” from the deep peroneal nerve injection site to that of the posterior tibial nerve. The superficial peroneal and sural nerves are similarly injected by subcutaneous field block connecting the deep peroneal nerve site to the achilles tendon moving the needle laterally and posteriorly beneath the lateral malleolus (Figure3). A total of 3-4 mL is used for each needle length. The total local anesthetic used is 25-30 mL per foot. Paresthesias are not sought, not necessary, and should be avoided during ankle block.

### **Choice of Local Anesthetic**

The choice of local anesthetic is dictated by the anesthetic or analgesic needs of the patient. The most commonly used drugs are intermediate-acting (2% lidocaine, 1.5% mepivacaine) or long-acting (0.75% bupivacaine, 1.0% ropivacaine) amide local anesthetics. Plain solutions of drugs should be used since addition of vasoconstrictors such as epinephrine is contraindicated and may lead to vascular insufficiency, because the injections are made near terminal arteries. This consideration is especially important in vascular or diabetic patients with pre-existing vascular compromise. Skin sloughing or ulcers may also result from use of added vasoconstrictors. Addition of bicarbonate to neutralize the pH of the intermediate duration amides decreases discomfort during injections and improves patient tolerance.

The use of plain lidocaine results in a dose-dependent duration of anesthesia from 2-4 hours and mepivacaine, 3-6 hours. These drugs are indicated for soft tissue procedures such as excision of neuroma, where prolonged analgesia is usually not needed. Use of long-acting local anesthetics such as bupivacaine may result in greater than 48 hours of anesthesia and analgesia following single injections and is therefore ideal for surgery on the joints and bones of the foot. The reasons for such prolonged anesthesia is that application of an ankle tourniquet prevents the anesthetic from being metabolized and allows for dense saturation of the nerves.

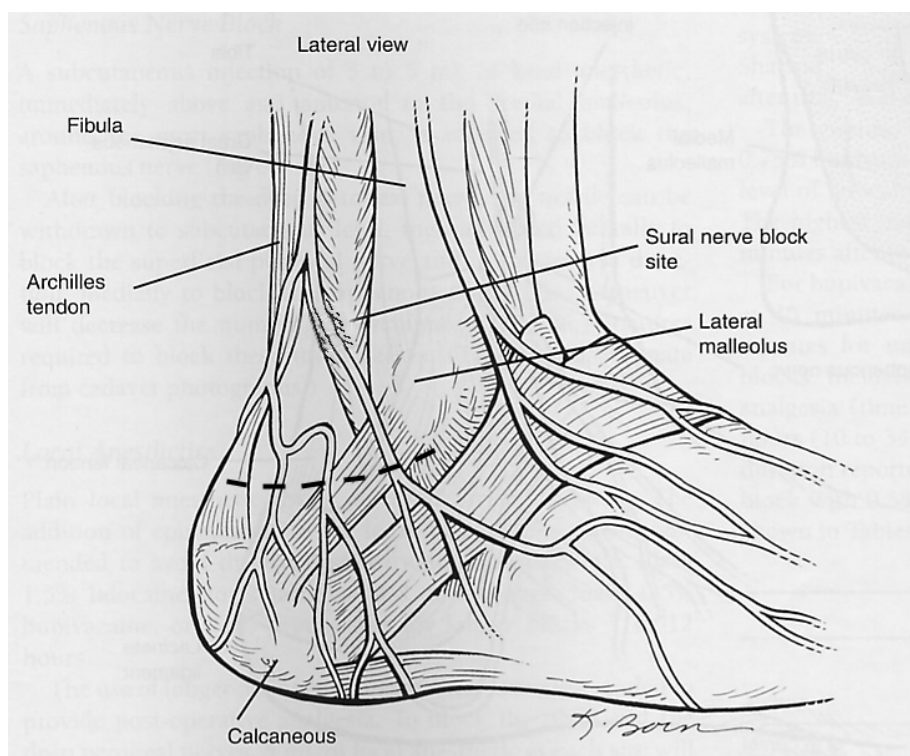


Figure 3. Site of injection for sural nerve block. Adapted from Concepcion M. Ankle block. *Tech Reg Anesth Pain Med* 1999; 3: 241.

### **Complications**

Ankle block is among the safest regional anesthetics if performed properly. It is almost devoid of physiological side effects and is therefore ideal when anesthetizing patients who are very ill, such as diabetics or vascular surgery patients presenting for transmetatarsal or toe amputation. Several studies support the safety of the ankle block.<sup>4,6,7</sup> Persistent paresthesia may occur rarely.<sup>8</sup> Local

anesthetic toxicity may occur from direct intravascular injection if care is not taken in aspirating before injection, especially for periarterial injections. Following ankle block, plasma levels of local anesthetic are very small compared to other regional anesthetics. This results from decreased vascular absorption, especially in patients with pre-existing vascular disease. Favoring decreased systemic absorption is the use of an ankle tourniquet which prevents absorption throughout the surgical procedure in most cases. Mineo and Sharrock<sup>3</sup> found peak plasma levels of only about 0.5 µg/mL following the use of 30 mL 0.75% plain bupivacaine for bilateral ankle block.

## Conclusions

Ankle block is a simple, effective, and extremely safe regional anesthetic for foot surgery. It can be quickly mastered. Use of the block results in effective postoperative analgesia, but allows for rapid recovery and early discharge of a fully ambulating patient for day surgery. By contrast to general or axial anesthesia, ankle block is not associated with physiological side effects. Ankle block is only rarely associated with significant complications. Use of the block should be encouraged when possible, especially in the patient for whom general or axial anesthesia poses significant hemodynamic or pulmonary risk.

## References

1. Concepcion M: Ankle block. *Techniques in Regional Anesthesia and Pain Management* 1999; 3: 241-246
2. Sharrock N, Waller J, Fierro L: Midtarsal block for surgery of the forefoot. *British Journal of Anaesthesia* 1986; 58: 37-40
3. Mineo R, Sharrock N: Venous levels of lidocaine and bupivacaine after midtarsal ankle block. *Regional Anesthesia* 1992; 17: 47-49
4. Sarrafian S, Ibrahim I, Breihan J: Ankle-foot peripheral nerve block for mid and forefoot surgery. *Foot and Ankle* 1983; 4: 86-90
5. Urmey W, Grossi P: Percutaneous electrode guidance (PEG): A noninvasive technique for pre-location of peripheral nerves to facilitate nerve block. *Regional Anesthesia and Pain Medicine* 2001; 27: 261-67
6. Wassef M: Posterior tibial nerve block. A new approach using the bony landmark of the sustentaculum tali. *Anaesthesia* 1991; 46: 841-844
7. Kofoed H: Peripheral nerve blocks at the knee and ankle in operations for common foot disorders. *Clinical Orthopedics* 1982; 168: 97-101
8. Kay J: Ankle Block. *Techniques in Regional Anesthesia and Pain Management* 1999; 3: 3-8